

Chronic volar distal radioulnar joint instability: joint capsular plication to restore function

Kelly Johnston, MD*
D'Arcy Durand, MD†
Kevin A. Hildebrand, MD*

From the *University of Calgary and the Calgary Health Region, Calgary, and the †University of Alberta, Edmonton, Alta.

Presented at the 61st Annual Meeting of the Canadian Orthopaedic Association, Jun. 2-4, 2006, Toronto, Ont.

Accepted for publication
Nov. 19, 2007

Correspondence to:
Dr. K.A. Hildebrand
Department of Surgery
University of Calgary
3280 Hospital Drive NW
Calgary AB T2N 4Z6
fax 403 270-3679
hildebrk@ucalgary.ca

Background: Volar instability of the distal radioulnar joint (DRUJ) is uncommon, and there is little written about it. The purpose of this study is to describe a new procedure to treat volar DRUJ instability and to present the outcomes of patients who received this unique surgical repair at a minimum of 1 year follow-up.

Methods: We performed a retrospective case series of 6 consecutive patients treated with a volar and dorsal capsular plication procedure by an upper extremity specialist surgeon at a teaching hospital between April 1999 and October 2004. We evaluated measures, including wrist range of motion, grip strength, radiographs, Disabilities of the Arm, Shoulder and Hand (DASH) questionnaire and Patient-Rated Wrist Evaluation (PRWE), at final follow-up.

Results: Five of 6 patients had resolution of pain and instability symptoms. The average difference in range of motion between operative and contralateral sides was -7° flexion, 2° extension, 4° radial deviation, 2° ulnar deviation, -17° supination and -2° pronation. Average grip strength measured 83% of the uninjured side. The average DASH score was 13.5 (range 0-46.7), and the average PRWE score was 26.7 (range 0-70). One patient had a low ulnar neuropathy, which resolved. One patient fractured the temporary DRUJ stabilization screw and had radiographic evidence of nonbridging heterotopic ossification.

Conclusion: Joint capsular plication for DRUJ has not yet been described in the literature. It is less elaborate in that it does not require a tendon graft with bone tunnels. The results at an average 16.5 months postoperatively are promising.

Contexte : L'instabilité palmaire de l'articulation radiocubitale distale est rare et peu de choses ont été écrites à ce sujet. Le but de la présente étude est de décrire une nouvelle intervention pour le traitement de l'instabilité palmaire de l'articulation radiocubitale distale et de présenter les résultats obtenus chez des patients qui ont bénéficié de cette réparation chirurgicale unique, après un suivi minimum d'un an.

Méthodes : Une analyse rétrospective a regroupé une série de 6 patients consécutifs traités par plicature capsulaire palmaire et dorsale réalisée par un chirurgien spécialiste des membres supérieurs dans un hôpital universitaire, entre avril 1999 et octobre 2004. Nous avons tenu compte de divers paramètres, dont l'amplitude de mouvement du poignet, la force de préhension, les radiographies, les résultats au questionnaire DASH (pour Disabilities of the Arm, Shoulder and Hand) et à l'échelle PRWE (pour Patient-Rated Wrist Evaluation), lors du suivi final.

Résultats : Chez 5 patients sur 6, les symptômes de douleur et d'instabilité sont rentrés dans l'ordre. La différence d'amplitude de mouvement moyenne entre le côté opéré et l'autre était de -7° pour la flexion, 2° pour l'extension, 4° pour la déviation radiale, 2° pour la déviation cubitale, -17° pour la supination et -2° pour la pronation. La force de préhension moyenne était de 83 % par rapport au côté indemne. Le score DASH moyen était de 13,5 (entre 0 et 46,7) et le score PRWE moyen était de 26,7 (entre 0 et 70). Un patient a présenté une neuropathie cubitale basse qui s'est résorbée. La vis de stabilisation de l'articulation radiocubitale distale s'est cassée chez 1 patient, et la radiographie révélait une ossification hétérotopique.

Conclusion : La plicature capsulaire de l'articulation radiocubitale distale n'avait encore fait l'objet d'aucune description dans la littérature. L'intervention est plus simple, en ce sens qu'elle ne requiert pas de greffon tendineux au niveau des tunnels osseux. Les résultats observés au moment du suivi postopératoire moyen, à 16,5 mois, sont prometteurs.

Chronic instability of the distal radioulnar joint (DRUJ) can lead to substantial pain, decreased grip strength and other mechanical symptoms.¹ The most common form of instability is described as dorsal DRUJ instability, whereby the distal ulna is dorsally displaced with respect to the distal

radius.² There are very few studies in the literature reporting on chronic volar DRUJ instability.^{1,3-8} This condition results in a prominent ulnar head on the volar aspect of the wrist and is most pronounced in full supination. The surgical techniques used to treat dorsal DRUJ instability have been applied to chronic volar instability.^{1,3-7} Apart from the notch osteoplasty described by Wallwork and colleagues,⁸ no procedure has been specifically designed to treat volar DRUJ instability.

Owing to recent advances in our understanding of the stabilizers of the DRUJ, new methods for stabilizing this joint are emerging. It is well recognized that there are bony and soft-tissue stabilizers of the DRUJ. The triangular fibrocartilage complex (TFCC) with its associated volar and dorsal radioulnar ligaments is recognized as the chief soft-tissue stabilizer of this articulation. Over the last 20 years, the literature has focused on the radioulnar ligaments, and only recently has the controversy over the relative ligament tensioning and translational stabilization during prosupination been settled. Most studies agree that in supination the volar radioulnar liga-

ments become taut and provide the primary restraint to translational movement at the DRUJ, and the reverse is true for forearm pronation.⁹⁻¹² However, most authors feel that both volar and dorsal radioulnar ligaments are important for translational stabilization of the DRUJ, especially in cases of gross instability.^{1,2,9}

The joint capsule is being increasingly recognized as a key contributor to DRUJ stability.^{9,13,14} Wong and colleagues¹⁵ report a case series of 6 patients with dorsal DRUJ instability and satisfactory results following dorsal capsular plication. In addition, Watanabe and colleagues¹³ performed a cadaveric sectioning study of the joint capsule and concluded that capsular plication would provide a useful adjunct to a DRUJ ligament repair or reconstruction.

Given that the joint capsule and radioulnar ligaments are intimate anatomically, we developed a plication procedure including joint capsule and radioulnar ligaments to treat volar DRUJ instability. The objective of our study was to report the outcomes of 6 patients with volar DRUJ instability after a direct repair of the volar and dorsal capsule and radioulnar ligaments.

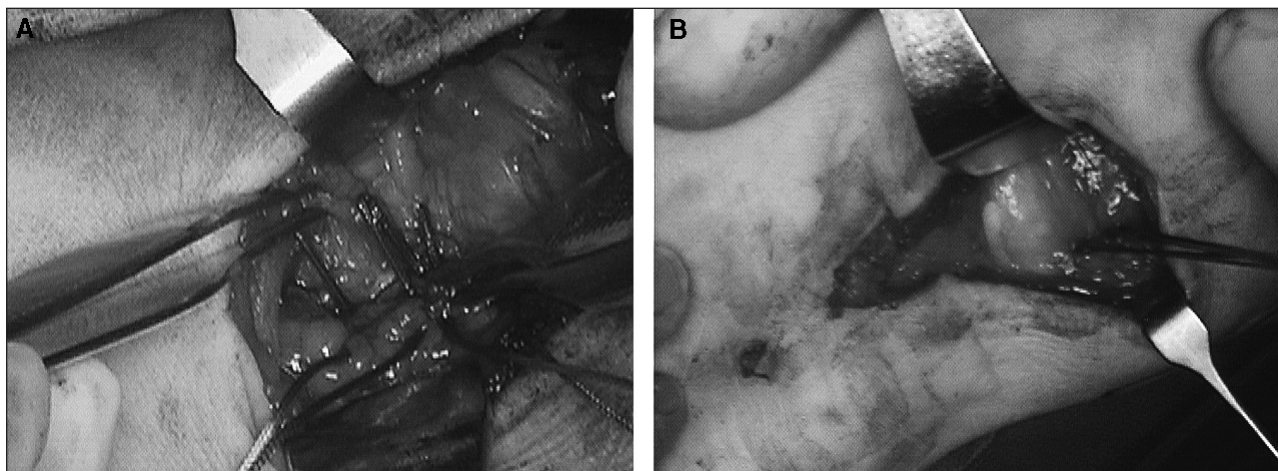


Fig. 1. Volar capsule elliptical excision and plication. Sutures are placed (A) and tied (B).

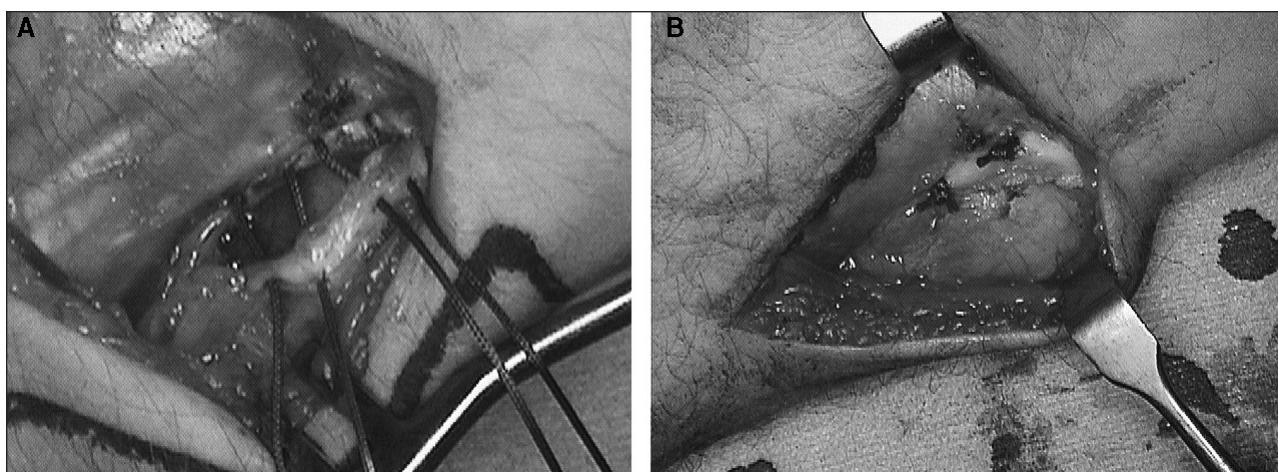


Fig. 2. Dorsal capsule plication. Sutures are placed (A) and tied (B).

METHODS

Participants

Between 1999 and 2004, 6 consecutive patients had surgery for volar DRUJ instability. An upper extremity specialist orthopedic surgeon (K.A.H.) performed the surgeries. The surgical indication was posttraumatic chronic volar instability of the DRUJ that failed conservative management, which consisted of splinting and physiotherapy. The patients presented with ulnar-sided wrist pain, loss of forearm rotation and clunking or popping with forearm rotation in a supinated position. The surgeon performed physical examinations to assess the differences between the affected wrist and the contralateral unaffected wrist in all patients.

Surgical procedure

With the patient under general anesthesia and tourniquet control, the surgeon positioned the affected wrist on a radiolucent arm table with the patient in the supine position. He used a volar-ulnar approach to the distal radioulnar joint, protecting the ulnar neurovascular structures.¹⁶ The interval was between the flexor carpi ulnaris and the extrinsic digital flexors. The capsule was redundant in this location. The surgeon removed an ellipse of tissue 2–4 mm wide from the capsule with the long axis oriented in the proximal to distal direction. The capsulotomy extended to the TFCC, thus including the volar DRUJ ligament. He then placed 2 heavy, braided non-absorbable sutures in a vest-over-pants fashion with 2-mm overlap (Fig. 1), leaving the sutures untied. He then used a dorsal approach to the DRUJ by coming through the extensor retinaculum over the fifth extensor compartment. The surgeon mobilized the extensor digiti minimi to expose the dorsal DRUJ capsule. The dorsal capsule was not as redundant, and he incised it longitudinally, including the dorsal DRUJ ligament, without excising tissue. He placed 2 heavy, braided nonabsorbable sutures in a vest-over-pants fashion with 2-mm overlap, leaving them untied (Fig. 2). He then reduced the DRUJ in pronation and transfixed it with a fully threaded 3.5-mm cortical screw, proximal to the DRUJ through a separate incision (Fig. 3). At this point, the surgeon tied the plication sutures to complete the capsular repair. He repaired the extensor retinaculum with the extensor digiti minimi deep to the retinaculum. He closed the skin incisions with absorbable monofilament suture material. He used an above-elbow posterior splint with 90° of flexion at the elbow, the forearm fully pronated and the wrist in neutral position. The surgeon examined the wounds 2 weeks postoperatively and placed the patients in a Munster-type cast for another 8 weeks. This cast was similar to a below-elbow cast incorporating the wrist, but it had extensions that included the

medial and lateral epicondyle and supracondylar ridge of the humerus to limit prosupination while allowing flexion-extension of the elbow. Ten weeks after surgery, the surgeon removed the screw in the operating room under a general anesthetic. Physiotherapy was started after screw removal. Physiotherapy focused on improving forearm rotation, wrist and elbow motion and hand dexterity. Strengthening was allowed 6–8 weeks after motion exercises began. Static progressive or dynamic splints were not used.

The surgical procedure was not entirely uniform in all patients. The youngest patient (patient 1) did not have a screw holding the DRUJ reduced, but had the procedure performed in maximal pronation and received an above-elbow cast to maintain pronation. This same patient received only the volar plication procedure. Immobilization time and postimmobilization physiotherapy progressed as previously described. Patient 3 received a wrist arthroscopy while under anesthesia immediately before the stabilization procedure. The surgeon identified no significant TFCC tear and therefore performed the described procedure.

The results of surgery were evaluated at an average of 16.5 months postoperatively (range 11–26 mo). The treating surgeon (K.A.H.) collected clinical measures, including wrist range of motion (hand-held goniometer) and grip strength measurements (Jamar dynamometer). The surgeon took 3 sequential grip strength measurements and averaged them on each side. The range of motion was expressed as an operative minus contralateral difference, whereas grip strength values were reported as a percentage compared with the opposite side at the last follow-up visit. The surgeon administered 2 validated, limb-specific health outcome tools at the final follow-up visit to assess surgical outcome from the patients' perspective. These included the Disabilities of the Arm, Shoulder, and Hand questionnaire (DASH) and Patient-Rated Wrist Evaluation (PRWE).¹⁷ From a chart review, we documented complications related to the treatment.

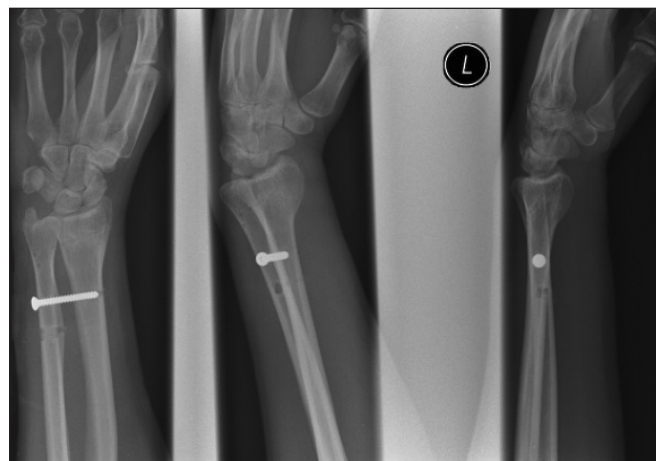


Fig. 3. Postero-anterior, oblique and lateral radiographs with the distal radioulnar joint (DRUJ) reduced and temporary DRUJ screw in place.

RESULTS

Patient characteristics are summarized in Table 1 and Table 2. There were 2 male and 4 female patients. The dominant arm was involved in 4 of the 6 patients. Five patients had previous distal radial metaphyseal fractures, and 1 patient had a previous distal radius and ulna shaft fracture. All previous fractures had been treated nonsurgically, and all fractures united within 20° of normal distal radius sagittal alignment. No patient had radiographic evidence of DRUJ arthritis, which was considered to be a contraindication to our procedure. Patient age ranged from 10 to 36 years at the time of the surgical procedure. The average time from initial injury to surgery was 30 months.

Our physical examination revealed differences between the affected and contralateral wrists, including tenderness on palpation of the DRUJ with a primarily volar DRUJ instability whereby the ulnar head was most prominent on the volar surface of the wrist with a dorsal concavity over the ulnar head and neck in supination. Increasing supination accentuated the deformity. There was increased volar translation of the ulna with respect to the radius under surgeon-applied stress with the forearm in neutral rotation and in maximum supination, suggesting the volar capsular and ligamentous restraints did not become taut. Patient 2 had to manually manipulate the ulna volarly to achieve supination. Patient 4 had a visible sudden pop of the ulnar head with volar subluxation of the ulna as the forearm supinated beyond 70° and with reduction of the ulna around 70° supination as the forearm pronated from maximal supination. There were no detectable side-to-side differences in dorsal DRUJ stability testing analogous to the volar stability testing described.

The surgeon successfully treated the instability of the DRUJ in 5 of the 6 patients. In these patients, the presenting pain and instability resolved. The health outcome instruments revealed an average postoperative DASH score of 13.5 and an average PRWE score of 26.7

(Table 3). The side-to-side range of motion comparisons at last follow-up showed an average loss of 17° of supination and 7° of flexion (Table 3). On average, there was little side-to-side difference in the other motions measured (Table 3). Grip strength measures averaged 83% of the contralateral side. There was no evidence of clunking of the ulnar head with forearm rotation, even in patient 4. Her recurrent instability findings were primarily pain with DRUJ translation on physical exam manoeuvres.

Three complications developed in 2 patients (Table 3). A radiograph revealed that patient 3 fractured the temporary DRUJ screw and had some heterotopic ossification between the radius and ulna around the screw. There appeared to be little effect on the forearm rotation, as the limitation in this patient (20°) was slightly above the group average (17°). Patient 4 experienced a partial low ulnar neuropathy postoperatively, which resolved in 7 months with conservative management.

DISCUSSION

Very little has been written on the treatment of volar DRUJ instability. Our case series describes a surgical procedure that can be used to treat this condition and avoid the complexities of tendon grafts and tethers typically used in reconstructions for dorsal DRUJ instability. The procedure successfully stabilized volar DRUJ instability in 5 of 6 patients. Our study also showed a trend toward loss of supination range of motion and grip strength, at least in the short-term. However, the health outcome measurement tools indicate a favourable outcome despite grip strength deficit and mild loss of supination. The principles of the procedure for chronic volar DRUJ instability derive from biomechanical studies indicating that volar DRUJ ligaments and capsule prevent the ulna from translating excessively in a volar direction with respect to the radius.⁹⁻¹² The redundant volar capsule has an ellipse of tissue excised with plication of the remaining volar capsule and ligaments. This was combined with a dorsal capsule

Table 1. Summary of patient characteristics

Patient no.	Sex	Age, yr	Injured hand	Cause of injury	Time from injury to surgery, mo	Symptoms	Radiograph
1	M	10	R*	Fall from bike	14	Instability	Remodeled distal both bones forearm fracture
2	F	18	L*	Ground level fall	84	Ulnar wrist pain and instability	Base ulnar styloid nonunion
3	M	14	R*	Snowboarding	11	Ulnar wrist pain and instability	Base ulnar styloid nonunion, remodeled distal radius fracture
4	F	23	R	Ground level fall	36	Ulnar wrist pain and instability	Tip ulnar styloid nonunion
5	F	36	L	Snowboarding	18	Ulnar wrist pain and instability (previous pseudomonas infection in hand, unable to make full fist)	Healed base ulnar styloid fracture
6	F	21	R*	Skiing	18	Ulnar wrist pain and instability	Tip ulnar styloid nonunion
Mean		20			30		
SD		9			27		

F = female; L = left; M = male; R = right; SD = standard deviation.
*Indicates dominant arm.

and ligament plication, decreasing the volume of the stabilizing structures.

The capsule has been shown to impart significant stability to the DRUJ.^{9,13-15,18} Gofton and colleagues¹⁸ compared 4 different DRUJ instability reconstruction surgeries in cadavers and showed that a dorsal and volar capsular repair was as effective as the other 3 options and most closely restored normal DRUJ kinematics. Their results strongly support the surgical procedure outlined in our study. These same authors note the possibility of soft-tissue attenuation in chronic instability patterns, thereby preventing a simple capsular repair surgery. At the very least, they recommend preserving capsular tissue and including a capsular repair in any stabilizing procedure. In our study, redundant volar capsular tissue was found and excised to see the overlap of the capsule more easily and to further reef this structure. Perhaps this tissue should be preserved during plication to reinforce the capsular tissue. The one failure in our series may relate to the fact that the volar tissue was attenuated.

We found that this procedure resulted in an average loss of 17° degrees of supination on side-to-side comparisons. Bowers¹⁹ has criticized all DRUJ reconstructions for obtaining anteroposterior stability at the expense of rotational motion. There is so little in the literature on volar DRUJ instability reconstructions that it is difficult to compare our

results. Adams and Berger¹ studied 14 patients with DRUJ instability, 10 of whom had bidirectional instability, 2 with pure volar instability. They used a free palmaris longus autograft to reconstruct the radioulnar ligaments. No capsular reefing was performed. In contrast to our study, they report loss of both supination and pronation at a minimum 1 year postoperatively. The loss was mild, approximating 90% of preoperative rotation. Most of the other reports on volar DRUJ instability are limited to case reports and describe novel reconstructions using tendon grafts to tether the radius to the ulna.^{3,6,7} These papers do not report specific loss of supination; however, there is variable loss of motion in other planes. Wong and colleagues¹⁵ report the largest case series for dorsal DRUJ instability treated by capsular plication — a procedure similar to that in our study. In their series, neither a volar approach nor temporary radioulnar pinning was performed. With the exception of 1 patient, they reported no loss of forearm rotation at an average 16 months follow-up. Loss of pronation occurred in 1 patient. In our study, the minimal loss of supination did not seem to adversely affect these patients.

Our study revealed a grip strength deficit. This is consistent with all other studies for DRUJ instability reconstructions. Our results of 83% of the opposite side compared favourably with that reported in the literature.^{1,7,15} Grip strength, when expressed as a percentage compared with the normal side, is biased by hand dominance. In our study, the dominant hand was involved in 4 of the 6 patients, and so it is more likely that our finding is real. Once again, this finding did not seem to adversely affect our patients.

Finally, our study is the first one to our knowledge that used validated, limb-specific health outcome instruments. These tools correlated well with clinical assessment, as those patients with excellent outcomes had low scores and those who had complications had high scores. Patient 4 had the highest score, as surgery was not successful in stabilizing the joint. Patient 5 had some residual ulnar-sided

Table 2. Surgical intervention and postoperative management for each patient

Patient no.	Wrist scope	Volar capsular excision + plication	Dorsal capsular plication	Temporary screw	Munster cast
1	-	+	-	-	+
2	-	+	+	+	+
3	+	+	+	+	+
4	-	+	+	+	+
5	-	+	+	+	+
6	-	+	+	+	+

Table 3. Surgical results

Patient no.	Follow-up, mo	Grip strength*	Range of motion, °†						DASH	PRWE	Comments
			Flexion	Extension	Radial deviation	Ulnar deviation	Supination	Pronation			
1	14	100	-1	-2	0	2	-20	8	0	0	NA
2	26	81	-4	-1	2	0	-10	-2	2.5	4.5	NA
3	16	81	-10	-5	20	2	-20	0	4.2	5	Broken DRUJ screw, heterotopic ossification
4	19	79	-8	5	-5	0	-43	-18	46.7	70	Recurrent instability, ulnar neuropathy
5	13	74	-22	7	3	-1	-1	-1	18.3	54.5	NA
6	11	85	4	6	3	10	-5	0	9.2	26	NA
Mean	16	83	-7	2	4	2	-17	-2	13	26	
SD	5	9	9	5	8	4	15	9	17	29	

DASH = Disabilities of the Arm, Shoulder, and Hand questionnaire; DRUJ = distal radioulnar joint; NA = not applicable; PRWE = Patient-Rated Wrist Evaluation; SD = standard deviation.

*Grip strength is percent operated / contralateral side at final follow-up.

†Range-of-motion values show operated minus contralateral values at final follow-up, in degrees.

wrist pain despite DRUJ stability. Patient 5 had previous ipsilateral hand pathology following an infected intra-venous line that required surgical débridement, and this may have been a confounding variable reflected on the limb-specific health outcome instruments. A better design would be to compare these scores pre- and postoperatively. MacDermid and colleagues²⁰ studied patients treated for distal radius fractures and reported an average PRWE score of 13.5 at 12 months after injury. Another prospective study performed by MacDermid and colleagues²¹ examined DASH and PRWE scores after distal radius fracture in a cohort of 275 patients. Secondary compensation cases were reviewed separately from noncompensation cases. Average PRWE scores after 1 year were 34 for compensation and 13 for noncompensation patients. Average DASH scores after 1 year were 23 for compensation and 11 for noncompensation. These scores of a common wrist injury serve as a rough comparison to our results in about the same follow-up period.

Complications were present in 2 patients. We suspected the ulnar neuropathy to be secondary to using a smaller incision with excessive retraction. It is recommended that the incision be extended across the wrist flexion crease to the Guyon canal, thus decreasing the retraction force required to view the volar capsule. The second patient experienced heterotopic ossification around a broken screw. Although in our practice we will continue to use 3.5-mm screws for 10 weeks, if heterotopic ossification leading to synostosis is a consistent issue, then cast immobilization techniques will be used. If screw breakage is an issue, then either 2 screws or earlier removal of the screw with continued cast immobilization for 10 weeks total may be entertained.

There is controversy over the role a nonunion of the base of the ulnar styloid has with respect to stability of the DRUJ. The TFCC is attached to the base of the ulnar styloid, and it seems reasonable that a nonunion would contribute to instability. In our study, 2 patients had radiographic nonunions of the styloid base at the time of the surgical procedure. We ignored the nonunion in our surgical approach, and both patients had stable distal radioulnar joints at follow-up. The 1 patient who failed to stabilize in the initial surgery had a nonunion of the tip of the ulnar styloid, which does not affect the attachment of the TFCC. It appears that nonunion of the ulnar styloid was inconsequential in our patients, and fibrous stability was enough to anchor the TFCC. For our patients, reattachment of the ulnar styloid would not address the volar capsular redundancy, which appears to be the critical pathologic lesion in the 6 patients in our series who had chronic volar DRUJ instability.

Our study has limitations. First, we did not have a complete data set for preoperative measures, which is a common problem in retrospective studies. Preoperative range-of-motion measures were available for 4 of 6 patients. Performing final follow-up minus preoperative range-of-

motion calculations of the involved extremity, the motion differences were 14° flexion, 14° extension, 16° radial deviation, 3° ulnar deviation, -15° supination and 3° pronation. These values were close to or somewhat better than comparisons made for side-to-side differences at final follow-up (Table 3). For these measures, either method is comparable. However, preoperative and postoperative DASH and PRWE measures may have helped with the confounding factors in patient 5. Second, 2 of our patients were skeletally immature, and so the generalizability of these results to adults is questionable. Finally, although this is the largest reported series of chronic volar DRUJ stabilization, the numbers are small and the follow-up is limited to 16.5 months. Conclusions regarding long-term outcomes are thus limited, but in the interval of this follow-up, stability can be reliably achieved. The technique described is a simple procedure that does not require tendon grafts or bony tunnels in the distal ulna and recreates the native anatomy of this complex articulation. This soft-tissue procedure can be used alone when the distal radius sagittal alignment is within 20° of normal values, but may have to be combined with a distal radius osteotomy for sagittal malalignments greater than 20°.

Competing interests: None declared.

Contributors: Dr. Hildebrand designed the study. Dr. Johnston acquired the data. All authors analyzed the data, wrote and reviewed the article and gave final permission for publication.

References

- Adams BD, Berger RA. An anatomic reconstruction of the distal radioulnar ligaments for posttraumatic distal radioulnar joint instability. *J Hand Surgery [Am]* 2002;27:243-51.
- Kihara H, Short WH, Werner FW, et al. The stabilizing mechanism of the distal radioulnar joint during pronation and supination. *J Hand Surgery [Am]* 1995;20:930-6.
- Fulkerson JP, Watson HK. Congenital anterior subluxation of the distal ulna. A case report. *Clin Orthop Relat Res* 1978;131:179-82.
- Spicer DD, Hargreaves D, Eckersley R. Simultaneous dislocations of the radiocapitellar and distal radioulnar joints. *J Orthop Trauma* 2002;16:136-8.
- Sakota J, Kaneko K, Miyahara S, et al. Recurrent palmar dislocation of the distal radioulnar joint. A case report. *Chir Main* 2002;21:301-4.
- Kashyap S, Fein L. Surgical correction of recurrent volar dislocation of the distal radioulnar joint. A case report. *Clin Orthop Relat Res* 1991;266:85-9.
- Sanders RA, Hawkins B. Reconstruction of the distal radioulnar joint for chronic volar dislocation. A case report. *Orthopedics* 1989;12:1473-6.
- Wallwork NA, Bain GI. Sigmoid notch osteoplasty for chronic volar instability of the distal radioulnar joint: a case report. *J Hand Surgery [Am]* 2001;26:454-9.
- Ward LD, Ambrose CG, Masson MV, et al. The role of the distal radioulnar ligaments, interosseous membrane, and joint capsule in distal radioulnar joint stability. *J Hand Surgery [Am]* 2000;25A:341-51.
- Schuind F, An KN, Berglund L, et al. The distal radioulnar ligaments: a biomechanical study. *J Hand Surgery [Am]* 1991;16A:1106-14.
- Acosta R, Hnat W, Scheker LR. Distal radio-ulnar ligament motion during supination and pronation. *J Hand Surgery [Br]* 1993;18:502-5.

12. Adams BD, Holley KA. Strains in the articular disk of the triangular fibrocartilage complex: a biomechanical study. *J Hand Surgery [Am]* 1993;18:919-25.
13. Watanabe H, Berger RA, An KN, et al. Stability of the distal radioulnar joint contributed by the joint capsule. *J Hand Surgery [Am]* 2004;29:1114-20.
14. Kleinman WB, Graham TJ. The distal radioulnar joint capsule: clinical anatomy and role in posttraumatic limitation of forearm rotation. *J Hand Surgery [Am]* 1998;23:588-99.
15. Wong KH, Yip TH, Wu WC. Distal radioulnar joint dorsal instability treated with dorsal capsular reconstruction. *Hand Surg* 2004;9:55-61.
16. Pourgiezis N, Bain G, Roth J, et al. Volar ulnar approach to the distal radius and carpus. *Can J Plast Surg* 1999;7:273-7.
17. MacDermid JC, Richards RS, Donner A, et al. Responsiveness of the short form-36, disability of the arm, shoulder, and hand questionnaire, patient-rated wrist evaluation, and physical impairment measurements in evaluating recovery after a distal radius fracture. *J Hand Surgery [Am]* 2000;25:330-40.
18. Gofton WT, Gordon KD, Dunning CE, et al. Comparison of distal radioulnar joint reconstructions using an active joint motion simulator. *J Hand Surgery [Am]* 2005;30:733-42.
19. Bowers W. The distal radioulnar joint. In: Green DP, Hotchkiss RN, editors. *Operative hand surgery*. New York (NY): Churchill Livingstone; 1993. p. 973-1020.
20. MacDermid JC, Roth JH, Richards RS. Pain and disability reported in the year following a distal radius fracture: a cohort study. *BMC Musculoskelet Disord* 2003;4:24.
21. MacDermid JC, Richards RS, Roth JH. Distal radius fracture: a prospective outcome study of 275 patients. *J Hand Ther* 2001;14:154-69.

Canadian Surgery FORUM

The Canadian Surgery FORUM canadien de chirurgie will hold its annual meeting Sept. 10–13, 2009, in Victoria, British Columbia. This interdisciplinary meeting provides an opportunity for surgeons across Canada with shared interests in clinical practice, continuing professional development, research and medical education to meet in a collegial fashion. The scientific program offers material of interest to academic and community surgeons, residents in training and students.

The major sponsoring organizations include the following:

- The Canadian Association of General Surgeons
- The Canadian Society of Colon and Rectal Surgeons
- The Canadian Association of Thoracic Surgeons
- The Canadian Society of Surgical Oncology

Other participating societies include the American College of Surgeons, the British Columbia Surgical Society, the Canadian Association of Bariatric Physicians and Surgeons, the Canadian Association of Surgical Chairmen, the Canadian Association of University Surgeons, the Canadian Hepato-Pancreato-Biliary Society, the Canadian Undergraduate Surgical Education Committee, the James IV Association of Surgeons and the Trauma Association of Canada.

For registration and further information contact surgeryforum@rcpsc.edu; www.cags-accg.ca.

FORUM canadien de chirurgie

La réunion annuelle du FORUM canadien de chirurgie aura lieu du 10 au 13 septembre 2009 à Victoria en Colombie-Britannique. Cette réunion interdisciplinaire permet aux chirurgiens de toutes les régions du Canada qui s'intéressent à la pratique clinique, au perfectionnement professionnel continu, à la recherche et à l'éducation médicale d'échanger dans un climat de collégialité. Un programme scientifique intéressera les chirurgiens universitaires et communautaires, les résidents en formation et les étudiants.

Les principales organisations qui parrainent cette réunion sont les suivantes :

- L'Association canadienne des chirurgiens généraux
- La Société canadienne des chirurgiens du côlon et du rectum
- La Société canadienne de chirurgie thoracique
- La Société canadienne d'oncologie chirurgicale

Le American College of Surgeons, le British Columbia Surgical Society, le Canadian Association of Bariatric Physicians and Surgeons, le Canadian Association of Surgical Chairmen, l'Association canadienne des chirurgiens universitaires, le Canadian Hepato-Pancreato-Biliary Society, le Comité canadien de l'éducation chirurgicale de premier cycle, l'Association des chirurgiens James IV, et l'Association canadienne de traumatologie sont au nombre des sociétés qui appuient cette activité.

Pour vous inscrire, veuillez communiquer à surgeryforum@rcpsc.edu; www.cags-accg.ca.