

CASE NOTE

Persistent nonhealing skin fistulous tract after congenital diaphragmatic hernia repair

Julio C. Vasquez, MD*†
Efrain Montesinos, MD†
Jacob DeLaRosa, MD*
Juan J. Leon, MD*

From the *Portneuf Medical Center and Idaho State University, Pocatello, Idaho, and the †Thoracic and Cardiovascular Surgery Program, Dos de Mayo National Hospital, Lima, Peru

Correspondence to:

Dr. J.C. Vasquez
Portneuf Medical Center
777 Hospital Way
Pocatello, ID 83201
fax 208 239-2589
juliov@portmed.org

Infectious complications after surgical treatment for congenital diaphragmatic hernia (CDH) are rare.¹ We present the case of a patient with a non-healing skin fistula following surgical treatment for CDH.

CASE REPORT

A newborn boy had surgical repair of a CDH through a right subcostal incision. Surgeons closed the diaphragmatic defect with interrupted non-absorbable sutures. A wound abscess developed and was drained on postoperative day 10. For the next 11 years, seropurulent fluid drained from a skin fistula with its opening in the right subcostal scar. The patient received intermittent courses of antibiotics that stopped the drainage for days or weeks, only to resume thereafter. He was otherwise asymptomatic. There was no erythema or tenderness to palpation, and test results for fungus, atypical bacteria (*Nocardia* and *Actinomyces* species) and tuberculosis were negative. A computed tomography (CT) scan of the chest and abdomen (Fig. 1) revealed a contained, small herniation of the colon through the right diaphragm and a chronic posterior right subdiaphragmatic abscess (5 × 3 × 2 cm) with a fistulous tract going through the chest and upper abdominal wall toward a pin-point opening in the scar (Fig. 2). A fistulogram confirmed that the origin of the skin fistula was the subdiaphragmatic abscess.

The patient underwent surgery. We injected methylene blue into the skin opening and followed it with a metallic probe. We then completely unroofed and excised the fistula tract through an incision extending from the old scar

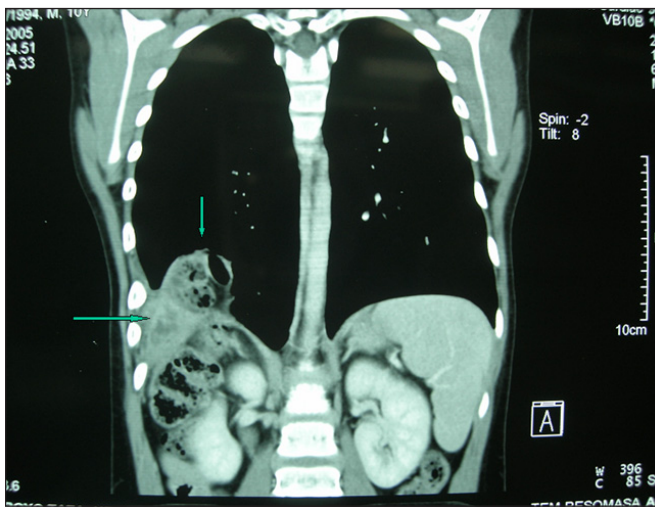


Fig. 1. Coronal computed tomography scan showing contained transdiaphragmatic herniation of the colon (vertical arrow) and right subphrenic abscess (horizontal arrow).

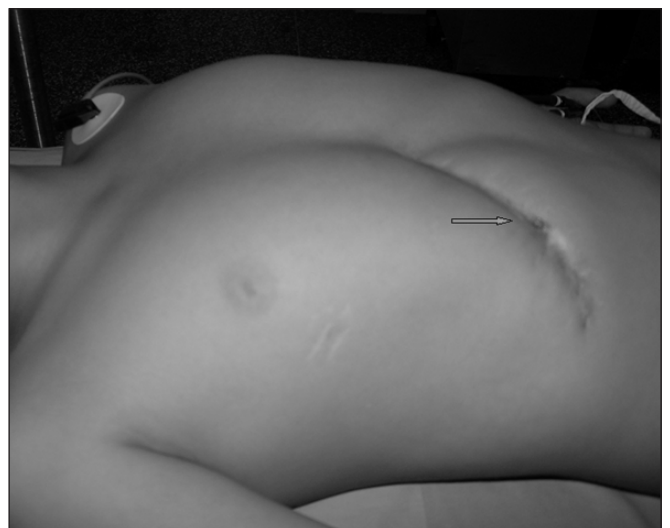

Fig. 2. Skin opening of fistulous tract (arrow) in a healed surgical subcostal scar.

toward the posterior eighth intercostal space, directed toward the abscess. We débrided the abscess wall and removed suture material that appeared to be the origin of infection. Severe inflammation and dense adhesions precluded safe dissection of the partially herniated colon. We left a Foley catheter inside the abscess cavity and placed a chest tube in the right pleural space, both of which were connected to -10 mL H₂O suction. A few days later, we removed the chest drain, and the patient was discharged home. We removed the Foley catheter on postoperative day 30. Six months later, a CT scan showed resolution of the subdiaphragmatic abscess. Two years later, the patient was asymptomatic without fistula recurrence.

DISCUSSION

The overall survival of newborns with CHD can be as high as 70%. Long-term sequelae include gastroesophageal reflux, bronchospasm and need for a gastrostomy tube.¹ Subdiaphragmatic abscess is uncommon, but it is a potentially serious condition. Percutaneous drainage with CT guidance is used for acute cases with up to an 80% success rate;² however, it is not indicated for chronic abscesses with thick walls.

The chronic subdiaphragmatic abscess in our patient might have been caused by persistent infection or foreign-body reaction to suture material. The indolent clinical course is probably related to isolation of the infected space due to encapsulation of the abscess and endothelialization of the fistulous tract. Similar cases have been described in the literature, including that of a patient with a cardiocutaneous fistula with a long transdiaphragmatic tract ending in the abdominal wall, which was secondary to infection caused by pledgets used during cardiac surgery.³

The differential diagnosis of chronic draining skin fistula in the chest or abdomen includes fungal infection (*Aspergillus*), bacterial infection (tuberculosis, nocardiosis and actinomycosis), inflammatory bowel disease, complicated diverticulitis and cancer.⁴ These conditions can be a diagnostic challenge and usually worsen without treatment. If they are ruled out, the recommended treatment is excision of the fistulous tract with débridement of the associated abscess and removal of the foreign body, if present.⁵

In summary, a chronic subdiaphragmatic abscess can form after surgical repair of CDH and can then result in the formation of a nonhealing skin fistula with persistent drainage. Complete excision of the fistulous tract and thorough débridement of the abscess cavity can successfully resolve this condition.

Competing interests: None declared.

References

1. Crankson SJ, Al Jadaan SA, Namshan MA, et al. The immediate and long term outcomes of newborns with congenital diaphragmatic hernia. *Pediatr Surg Int* 2006;22:335-40.
2. Gervais DA, Brown SD, Connolly SA, et al. Percutaneous imaging guided abdominal and pelvic abscess drainage in children. *Radiographics* 2004;24:737-54.
3. Danias PG, Lehman T, Kartis T, et al. Cardiocutaneous fistula. *Heart* 1999;81:325-6.
4. Kroe M, Shulman N, Kirsch CM, et al. An anterior mediastinal mass with draining sternal sinus tracts due to *Nocardia braziliensis*. *West Med J* 1997;167:47-9.
5. Kaul P, Qadri SSA, Riaz M. Chronic encapsulated mediastinal abscess presenting with remote cutaneous fistulization 12 years after redo aortic valve replacement for prosthetic valve endocarditis. *J Cardiothorac Surg* 2006;1:22.