

CASE NOTE

Spontaneous intrahepatic echinococcal cyst rupture in a patient with chronic hepatitis C infection

Manousos M. Konstadoulakis,
MD, PhD*
Ilias P. Gomatos, MD*
Levon Toufektzian, MD*
Stylios Katsaragakis, MD*
John Koskinas, MD†
Pantelis Antonakis, MD*
Nikolaos Nikiteas, MD‡
Emmanuel Leandros, MD*
Christos Tsigris, MD‡

From the *Hepatopancreatobiliary Unit, 1st Department of Propaedeutic Surgery, the †2nd Department of Internal Medicine and the ‡Laboratory of Surgical Research, 1st Department of Propaedeutic Surgery, Athens Medical School, Hippocraton Hospital of Athens, Athens, Greece

Correspondence to:
Dr. M.M. Konstadoulakis
Kalvou 24, Old Psychiko
154 52 Athens
Greece
fax 30-210-6722259
manousos.konstadoulakis@mountsinai.org

Echinococcal disease involves the liver in 70% of cases,¹ with communication rates between the cyst and the biliary tree ranging from 9% to 25%.² Various operative, laparoscopic, endoscopic or percutaneous methods³ have been proposed for the curative management of uncomplicated echinococcal cysts; however, in patients with hydatid cyst rupture into the alimentary or biliary tract, open operative management is mandatory.⁴ We report the case of a patient with cirrhosis and chronic hepatitis C (HCV) infection presenting with spontaneous rupture of an echinococcal liver cyst into the right segmental intrahepatic bile duct system.

CASE REPORT

A 58-year-old man was admitted to our department with a 5-day history of nausea and right upper quadrant pain and a 3-day history of jaundice and fecal discoloration. The patient was afebrile. Ultrasonographic workup of the upper abdomen revealed the presence of a large type III (Gharbi's classification)⁵ cystic mass in the right hepatic lobe occupying segments V and VI, with ipsilateral right intrahepatic bile duct dilatation. Laboratory tests revealed an elevated leukocyte count, eosinophilia, direct hyperbilirubinemia and elevated liver function. Serum antibody screening was positive for anti-echinococcal IgG antibodies and chronic HCV infection. We immediately started the patient on oral albendazole, and the magnetic resonance cholangiopancreatograph (MRCP) showed a large cystic mass measuring 9 cm (Fig. 1) with multiple intracystic loculations.

Jaundice resolved spontaneously after bowel rest and antimicrobial prophylaxis, obviating the need for performing endoscopic retrograde cholangiopancreatography (ERCP), and the patient was taken to the operating room, where we found a cirrhotic liver with a large intrahepatic echinococcal cyst. Following open cholecystectomy, we punctured the cyst wall and aspirated the cystic content. Once we injected 3% sodium chloride solution as a scolicidal agent, we removed the entire anterior cyst wall and the overlying liver parenchyma under 5 minutes of Pringle time ischemia using Metzenbaum scissors and clips. After liver reperfusion, meticulous hemostasis, débridement of the remaining calcified cystic wall and lavage of its contents occurred. During these steps, we discovered an oval communication with the right posterior intrahepatic bile duct measuring 1.5 cm in diameter on intraoperative ultrasound. We performed an open common bile duct exploration with meticulous clearance both proximally and distally to a longitudinal choledochotomy, while we advanced a 5-Fr Nelaton catheter anterogradely to catheterize the ampulla of Vater. We advanced a second 5-Fr Nelaton catheter until the liver surface was avulsed to catheterize the peripheral part of the communicating intrahepatic duct. We exteriorized the catheter through the abdominal wall, secured it in place and used it to stent the cystobiliary communication, which we repaired

with 4 interrupted transversely placed 6–0 PDS sutures. We repaired the common bile duct opening over a T-tube with interrupted 6–0 PDS sutures. We inserted 2 Jackson Pratt drains: one infrahepatically and the other within the residual cystic cavity.

We removed the infrahepatic drain on the fourth postoperative day. On postoperative day 11, we injected water-soluble contrast medium through the transcutaneous transhepatic catheter, demonstrating bile leak around the site of the intrahepatic bile duct repair. We also injected contrast medium through the T-tube with the same findings (Fig. 2). We transferred the patient to the ERCP suite, where we placed a plastic stent via the transcutaneous transhepatic biliary catheter and sealed the biliary communication.

Twenty-four hours later, a repeat contrast study from the T-tube (with the transcutaneous, transhepatic catheter closed) showed no signs of bile leak or stenosis. Subsequently, the T-tube was closed. On the 14th postoperative

day, the transcutaneous transhepatic catheter drained more than 150 mL, while the intracystic drain had an output of less than 30 cc of biliary fluid. On the 15th postoperative day, we removed the T-tube and closed the transcutaneous transhepatic catheter; we discharged the patient 2 days later (17th postoperative day). Six days later, we removed the intracystic drain while the transcutaneous, transhepatic catheter remained closed. On the 35th postoperative day, a repeat cholangiography had normal findings and we removed the transcutaneous transhepatic catheter. The patient's further postoperative course was uneventful; he remained free of disease 24 months after the initial surgery. During the 3 months immediately after surgery, the patient received oral albendazole, and we referred him to the Hepatology Department of our hospital for subsequent management of his chronic HCV infection.

DISCUSSION

Communications between the cyst and the biliary tree are seen in 9%–25% of patients with echinococcal disease.² Radical surgery, including complete removal of the cyst along with the pericyst, remains the curative therapy of choice. There is a general consensus that meticulous common bile duct exploration and clearance of the cystic material from the biliary tree with restoration of normal bile flow should be performed. Although anatomic or

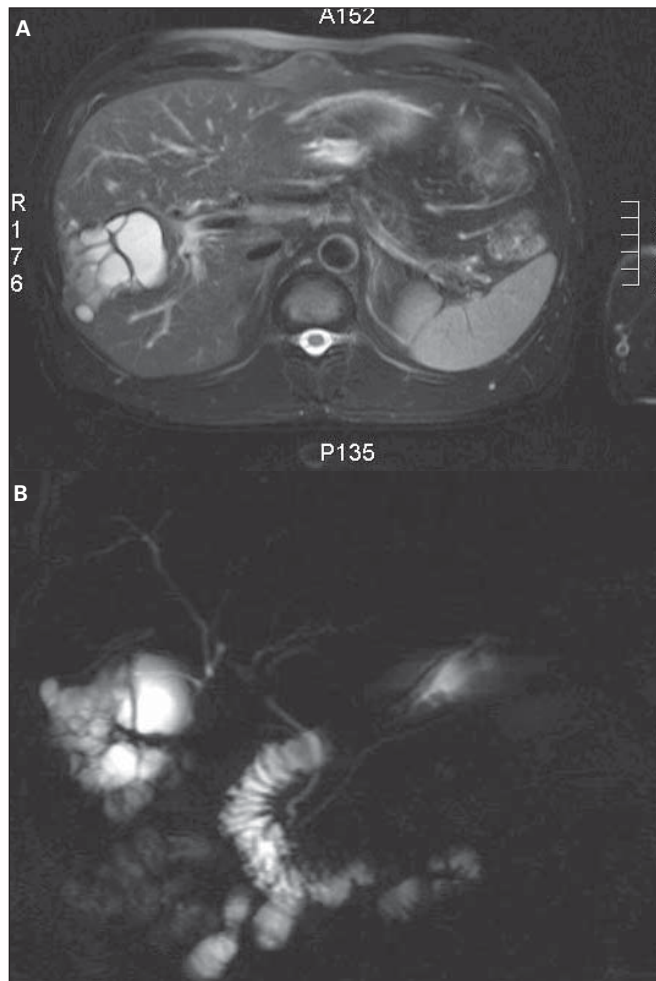


Fig. 1. Preoperative magnetic resonance cholangiopancreatography indicating a large echinococcal liver cyst communicating with the right posterior biliary system. (A) The transverse view shows the location of the cyst within the liver parenchyma, and (B) the coronal view shows the communication of the cyst with the biliary system.

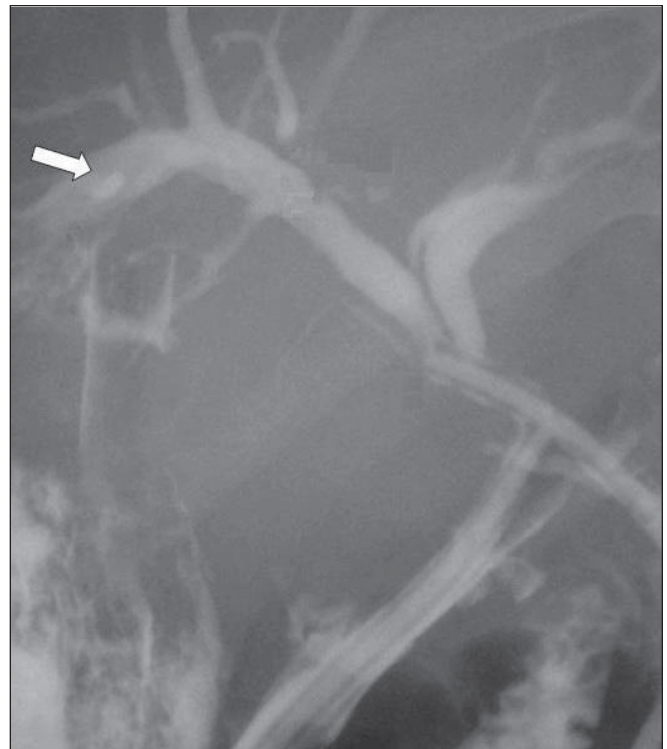

Fig. 2. Cholangiography performed via the T-tube demonstrating normal imaging of the common bile duct and the duodenum (11th postoperative day). There is a minor contrast medium leak from the right posterior segmental duct (arrow).

nonanatomic liver resections are suitable for most peripherally located cysts, true anatomic liver resections are strictly applied in patients with adequate hepatic reserve.

Regarding the echinococcal cyst in our patient, we performed partial liver resection with pericystectomy of 95% of the cyst wall, leaving only the part of the cyst invading the right hepatic duct. This approach allowed us to achieve macroscopically negative resection margins and preserve an adequate portion of an already compromised (due to cirrhosis) liver parenchyma while maintaining unobstructed bile flow from segments V, VII and VIII.

Management of the right hepatic duct remains controversial, ranging from primary repair and Kehr drainage to cystobiliary disconnection and wide cystojejunostomy. Although T-tube placement has been considered to be adequate when the biliary tract is cleaned of all cystic content, in our patient we chose to peripherally advance a second catheter toward the liver surface and use it both as a transcutaneous transhepatic catheter and as an internal stent for the primary repair of the cystobiliary communication. By preserving both the transcutaneous transhepatic catheter and the T-tube in situ we attained free access to the entire intra–extrahepatic biliary tree for future interventions. The transcutaneous transhepatic drainage catheter permitted access to more peripheral parts of the intrahepatic biliary tree (located near the liver surface),

which cannot be readily accessed via a T-tube; however, by occasionally opening and closing it we succeeded in controlling intrahepatic segmental bile duct pressure and potential leak when the T tube was removed and the intracavitary drain remained in situ. Moreover, catheterization and stent placement via the transcutaneous transhepatic biliary catheter permitted us to fix the bile leak without resorting to ERCP and the respective morbidity. Our strategy appears safe and may prove effective for the management of complicated hydatid disease in patients in whom major liver resection is contraindicated.

Competing interests: None declared.

References

1. Sayek I, Yalin R, Sanaç Y. Surgical treatment of hydatid disease of the liver. *Arch Surg* 1980;115:847-50.
2. Kornaros SE, Aboul-Nour TA. Frank intrabiliary rupture of hydatid hepatic cyst: diagnosis and treatment. *J Am Coll Surg* 1996;183:466-70.
3. Ozaslan E. Therapeutic endoscopic retrograde cholangiopancreatography and related modalities have many roles in hepatobiliary hydatid disease. *World J Gastroenterol* 2006;12:4930-1.
4. Jabbour N, Shirazi SK, Genyk Y, et al. Surgical management of complicated hydatid disease of the liver. *Am Surg* 2002;68:984-8.
5. Gharbi HA, Hassine W, Brauner MW, et al. Ultrasound examination of the hydatid liver. *Radiology* 1981;139:459-63.