

Computer-assisted FluoroGuide navigation of unicompartamental knee arthroplasty

Burton Ma, PhD*
 John Rudan, MD†
 Raja Chakraverty, MD†
 Heather Grant, MSc†

From the *School of Computing and the †Department of Surgery, Queen's University, Kingston, Ont.

Accepted for publication
 Nov. 14, 2008

Corresponding author:
 Ms. H. Grant
 Human Mobility Research Centre
 Kingston General Hospital
 76 Stuart St.
 Kingston ON K7L 2V7
 fax 613 549-2529
 granth@queensu.ca

Background: Most authorities recognize minimally invasive unicompartamental knee arthroplasty (UKA) as technically demanding with concerns regarding loss of implantation accuracy. We have previously reported on the potential inaccuracy of femoral intramedullary guides in UKA leading to poor component positioning. Our 3-dimensional analysis of alignment error showed that a short, narrow intramedullary rod inserted according to the manufacturer's specifications did not accurately find the direction of the anatomic axis, with errors occurring in both the coronal and sagittal planes. We sought to evaluate whether a fluoroscopic computer-assisted minimally invasive UKA procedure would improve the accuracy and precision in the placement of the femoral component in the coronal and sagittal planes compared with conventional surgery.

Methods: We performed a prospective study involving cohorts of 45 conventional versus 53 navigated UKAs. A single surgeon performed all surgeries over a 4-year period.

Results: Pain and knee function significantly improved in both surgical groups at 1 and 2 years after surgery. At a minimum of 1-year follow-up, radiographic evaluation revealed significant improvements in coronal alignment precision of the tibial component ($p = 0.026$) and sagittal alignment precision of the femoral component for the navigated group ($p = 0.037$). The use of a fluoroscopic computer-assisted technique did not significantly improve the accuracy of any of the alignment angles.

Conclusion: We cannot justify the additional expense and complexity imposed by fluoroscopic navigation despite the observed improvements in alignment precision. Improved positioning precision may translate into a greater number of long-term functional results, but larger, longer-term studies are needed.

Contexte : La plupart des autorités reconnaissent que l'arthroplastie unilatérale du genou (AUG) à effraction minimale est exigeante sur le plan technique et que la perte de précision de l'implantation soulève des préoccupations. On a déjà publié un rapport sur l'inexactitude possible des guides intramédullaires fémoraux dans des cas d'AUG qui entraînent un positionnement médiocre des pièces. Notre analyse tridimensionnelle de l'erreur d'alignement a révélé qu'une courte tige intramédullaire étroite insérée suivant les spécifications du fabricant n'a pas trouvé exactement la direction de l'axe anatomique et qu'il y a eu des erreurs dans les plans tant frontal que sagittal. Nous avons cherché à déterminer si une AUG à effraction minimale, assistée par ordinateur et fluoroscopie, améliorerait l'exactitude et la précision de la mise en place de la pièce fémorale dans les plans frontal et sagittal comparativement à l'intervention chirurgicale classique.

Méthodes : Nous avons effectué une étude prospective de cohortes comparant 45 AUG habituelles à 53 AUG assistées. Un seul chirurgien a pratiqué toutes les interventions chirurgicales sur une période de 4 ans.

Résultats : La douleur et la fonction du genou s'étaient améliorées considérablement chez les 2 groupes de patients 1 an et 2 ans après l'intervention. Au suivi d'au moins 1 an, l'évaluation radiographique a révélé des améliorations importantes de la précision de l'alignement frontal de la pièce tibiale ($p = 0,026$) et de la précision de l'alignement sagittal de la pièce fémorale chez les patients qui ont subi une intervention assistée ($p = 0,037$). La technique assistée par ordinateur et fluoroscopie n'a toutefois pas amélioré significativement l'exactitude des angles d'alignement.

Conclusion : Nous ne pouvons justifier la dépense supplémentaire et la complexité qu'impose la navigation par fluoroscopie, en dépit des améliorations observées de la précision de l'alignement. Une meilleure précision du positionnement peut augmenter le nombre de résultats fonctionnels à long terme, mais des études de plus grande envergure et à plus long terme s'imposent.

Mobile-bearing unicompartmental knee arthroplasty (UKA) is performed primarily for medial compartment osteoarthritis. Unicompartmental knee arthroplasty studies have reported mid- and long-term survivorships comparable to total knee replacement.^{1,2} However, most authorities recognize the UKA procedure as technically demanding when combined with the increasing emphasis of minimally invasive surgery, reducing surgical site visualization of anatomic landmarks and potentially resulting in component malpositioning.

A previous study reported on the potential inaccuracy of femoral intramedullary guides in UKA leading to poor component positioning, an accepted factor in failure of this procedure.³ The 3-dimensional analysis of alignment error using 20 cadaver femora showed that a short, narrow intramedullary rod inserted according to the manufacturer's specifications did not accurately find the direction of the anatomic axis, with errors occurring in both the coronal and sagittal planes.

Although fluoroscopic implantation for unicompartmental knee arthroplasty is not commonly performed, there are several reasons why we prefer this system. Fluoroscopic computer-assisted surgery does not require digitization of any registration points or anatomic landmarks, and therefore there is no requirement for additional pointing devices. Our experience shows it is easier and faster to acquire the necessary fluoroscopic images than to digitize registration points and manipulate the hip joint.

Finally, exposing the patient and the surgical team to the effects of ionizing radiation is minimized using the 2 fluoroscopic images (i.e., anteroposterior of the hip and lateral of the knee). Radiation exposure for the patient is much less than would be experienced if the patient had preoperative computed tomography (CT) scanning, as is required in CT-based computer-assisted methods.

Studies incorporating computer-assisted guidance and UKA have reported significantly more accurate alignments for the computer navigation groups compared with conventional surgical groups, specifically for the coronal and sagittal alignments.⁴⁻⁷ One study that used a fluoroscopy-based computer navigation system for total knee arthroplasty (TKA) showed significantly reduced variability in the coronal plane for the computer-assisted group compared with the conventional group.⁸ Also, a high correlation has been found between the full-leg standing radiographs and the computer navigation system for determining the mechanical alignment of the lower limb in the coronal plane.

Given the possible inaccuracies inherent in the component alignment with mechanical guidance, the purpose of our study was to evaluate a computer-assisted FluoroGuide system (iGO Technologies) to assist in the implantation of a series of unicompartmental arthroplasties. We posed the following research question: given 2 groups of UKA patients with similar demographic and clinical characteristics, will a fluoroscopic computer-assisted procedure

improve the accuracy and precision in the placement of the femoral component in the coronal and sagittal planes compared with conventional surgery? To date there appear to be no published comparable studies.

METHODS

Study population

Between January 2002 and May 2006, one of us (J.R.) performed 98 Oxford phase 3 (Biomet) UKA surgeries on patients with medial compartment arthritis in a prospective manner.⁹ The surgeon was experienced in conventional Oxford UKA and computer-assisted surgery in general. Some of the surgeries were performed using conventional guides, and some were performed using FluoroGuide (iGO Technologies) surgical navigation. All patients gave informed consent to undergo surgery provided they met the appropriate selection criteria: radiographs and symptoms of primarily medial compartment arthritis, functional anterior cruciate ligament clinically and confirmed intraoperatively, less than 15° of correctable varus deformity, less than 15° of flexion deformity, and pain and disability severe enough to warrant joint replacement.

Our original intent was to evaluate the radiographic alignment of the components achieved using fluoroscopic guidance in a consecutive series of patients; however, patients who did not wish to receive the computer-assisted treatment in place of conventional technique were also followed. The conventional technique cohort comprised patients who declined computer-assisted treatment and a small number of patients for whom equipment problems prevented the use of fluoroscopic guidance. Documented equipment problems included unavailability of the fluoroscope (i.e., damaged, out for repairs or being used in another surgery) and incorrect orientation of the operating room table for fluoroscope use. The events leading to a patient receiving conventional treatment were beyond our control and produced randomized but slightly unbalanced cohort sizes with no overt selection bias on our part. To rule out differences that could accidentally bias the outcomes, we collected preoperative clinical data and compared them between the 2 groups. Data included age, sex, operative side, knee pain, stiffness and function using the Medical Outcomes Study Short Form (SF-36) and Western Ontario and McMaster Universities (WOMAC) Osteoarthritis Index surveys.^{10,11} We obtained approval for this prospective, comparative study from our institution's ethics review board.

Surgical techniques

The surgeon carried out all operative procedures using standard Oxford instrumentation and following the standard technique. All procedures occurred under tourniquet

control with preoperative administration of antibiotic prophylaxis. The surgeon performed a minimally invasive medial arthrotomy without dislocating the patella and inspected the joint to confirm an intact anterior cruciate ligament.

The conventional surgical group had the components placed using the standard technique as described in the manufacturer's technique manual.⁹ The surgeon used conventional mills, saws and guides for the femoral component.

For the computer guidance group, at least 2 intraoperative fluoroscopic images were required (an anteroposterior image of the hip and a lateral image of the knee). Patients were positioned supine on a radiolucent table with the operative thigh resting on a supported gel bolster off the side of the table, allowing greater than 90° of knee flexion. The surgeon used the same conventional jigs and guides for both study groups with the exception of the femoral intramedullary (IM) rod, which was not required in the computer-assisted technique. Computer guidance was only used to facilitate tibial rotational implantation and femoral alignment in the sagittal and coronal planes.

The surgeon used a FluoroGuide computer-assisted guid-

ance system for the fluoroscopic group. This tracking system measures the position and orientation of rigid-body localizers, often called dynamic reference bodies (DRBs). This system is designed to accommodate a variety of trackers, and we used an infrared camera for tracking in this study (Polaris; Northern Digital). FluoroGuide tracks an ordinary fluoroscope via a frame, which acts as a DRB, clamped to the image intensifier. The frame is instrumented with a regular grid of small metal beads that appear in the fluoroscopic images; the beads are used to correct distortion in the images and to calibrate the location of the radiographic source.

The surgeon implanted a DRB on threaded posts through a small stab incision laterally in the supracondylar region of the femur. We used the tracked fluoroscope to acquire an anteroposterior image of the femoral head and a lateral image of the distal femur (Fig. 1). The anteroposterior image of the femoral head is easily acquired, but care must be taken to control for rotational error when acquiring the lateral image of the distal femur; we tried to ensure that the posterior condyles were approximately aligned in the image. The surgeon inserted a tensioner into the medial compartment with the knee in 90° of flexion to

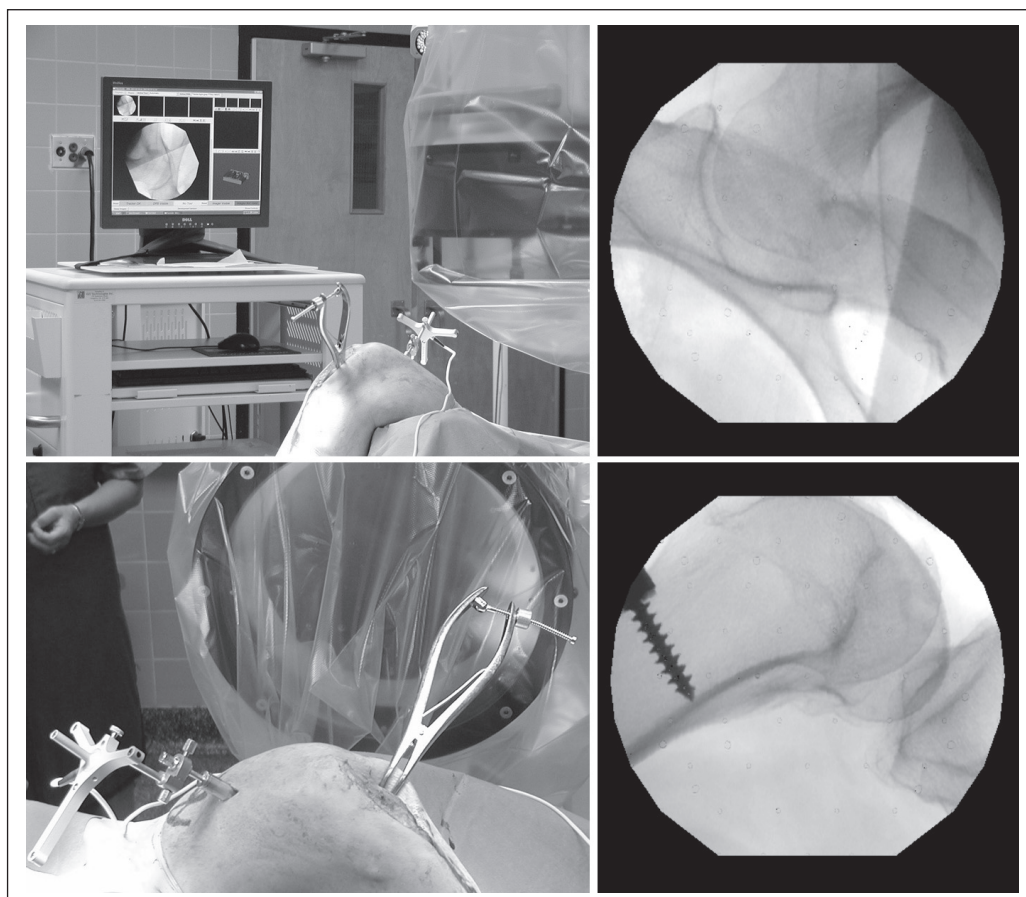


Fig. 1. Acquisition of the images of the femoral head in the coronal plane and the distal femur in the lateral plane. After the leg is strapped into a gel booster and a dynamic reference body (DRB) is implanted into the femur via a lateral stab incision, both the patient and fluoroscope are tracked during imaging. The femoral DRB provides the frame of reference for navigational guidance.

eliminate laxity in the medial collateral ligament. We calibrated a surgical drill, also instrumented with a DRB, with a pin in the chuck. The purpose of the calibration process was to find the location of the tip of the drill bit and the direction of the drill axis. Calibration was accomplished by manually spinning the drill chuck while the bit was inserted into a tracked calibration device. After calibration, FluoroGuide was able to show the real-time position and orientation of the drill in 2 fluoroscopic images. Using the calibrated drill, we inserted a pin into the tibia pointing toward the femoral head in the anteroposterior image and parallel to the distal femoral anatomic axis in the lateral image; the horizontal location was where the vertical cut should have passed through. When inserted in such a manner, the pin correctly defines the internal/external rotation of the vertical cut and the flexion/extension of the tibial cutting guide, and the navigation system is no longer needed to assist with the tibial cuts. We obtained an anteroposterior radiograph of the hip on a radiolucent bed on which the leg was draped to accommodate the excursion of the image intensifier. To minimize the number of radio-opaque images on radiography, we used a radiolucent bolster behind the knee.

The femoral drill guide was applied without intramedullary referencing. We recalibrated the drill with the 4-mm femoral drill bit in the chuck. With the tibial template, feeler gauge and femoral drill guide in place, the surgeon inserted the 4-mm drill bit into the upper hole of the drill guide. The guide was manipulated using the tracked drill so that the drill was pointing toward the centre of the femoral head in the anteroposterior image and parallel to the anatomic axis in the lateral image (Fig. 2). The surgeon then inserted the drill bit up to its stop, thus setting the correct alignment of the guide, and the remainder of the procedure was performed in the standard fashion.

We obtained anteroposterior and lateral views of all knees at 1-year follow-up. An independent orthopedic surgeon (R.C.), referencing off of the anatomic axis of both the femur and tibia, measured the component alignment in the sagittal and coronal planes. We then compared these measurements with the ideal component placement as outlined in the surgical technique manual (Fig. 3).⁹ Angles A and E are the femoral and tibial component axis angles, respectively, measured in the coronal plane. Angles B and F are the femoral and tibial component axis angles, respectively, measured in the sagittal plane.

Statistical analysis

We used descriptive statistics to summarize age and sex in both groups. We performed a residuals analysis to determine whether the data met the assumptions of parametric tests (i.e., normally distributed with equal variances). To compare groups on demographic, clinical and radiographic measurements, we used independent samples *t* tests, Levene's test for equality of variances and binomial tests. We also used χ^2 analyses to determine whether the proportion of patients with a measured alignment angle outside of the target range specified by the manufacturer was significantly different between groups. We examined differences in WOMAC and SF-36 pain and function scores between and within groups using independent and paired-samples *t* tests. In all tests, we considered an α value of 0.05 to be significant. We performed all analyses using SPSS 16.0 (SPSS Inc.).

We used the Oxford phase 3 unicompartmental knee arthroplasty surgical technique manual to determine the acceptable alignment ranges for the femoral component axis angle measured in the coronal plane needed for our power calculation.⁹ Based on the number of patients in each group and the respective standard deviations, our

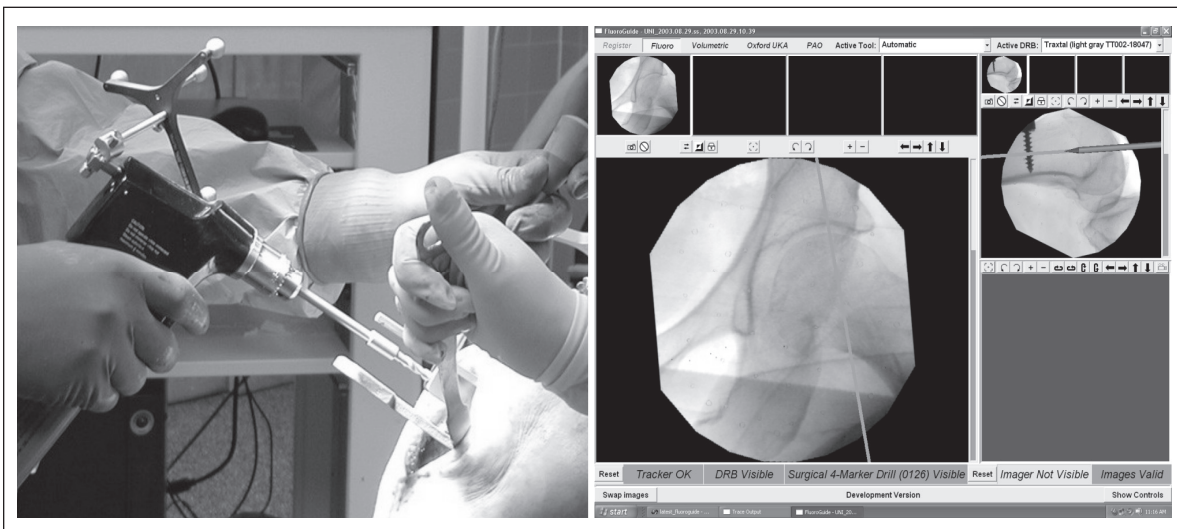


Fig. 2. To navigate the femoral reaming pin using a tracked surgical drill, the surgeon aligns the axis of the pin with the centre of the femoral head in the coronal plane and parallel to the posterior cortex in the sagittal plane.

sample had 95% power to detect a statistically significant difference between the 2 groups.

RESULTS

Of the 98 patients who underwent surgery during our study period, 45 had conventional surgery and 53 had surgery with FluoroGuide (iGO Technologies) surgical navigation. The conventional group comprised 22 men and 23 women with a mean age of 64 years. The FluoroGuide group comprised 30 men and 23 women with a mean age of 65 years. There were 25 left knees and 20 right knees in the conventional group and 26 left knees and 27 right knees in the FluoroGuide group.

There were no significant differences between the conventional and FluoroGuide groups in terms of age ($p = 0.44$), sex ($p = 0.54$) or operative side ($p = 0.55$). We observed no significant differences between the groups on any of the WOMAC (pain $p = 0.30$; stiffness $p = 0.89$; physical function $p = 0.41$) or SF-36 survey parameters preoperatively (physical component summary [PCS] $p = 0.41$; mental component summary [MCS] $p = 0.92$), at 1-year follow-up (pain $p = 0.65$; stiffness $p = 0.53$; physical function $p = 0.69$; PCS $p = 0.61$; MCS $p = 0.88$) or at 2-year

follow-up (pain $p = 0.50$; stiffness $p = 0.72$; physical function $p = 0.54$; PCS $p = 0.47$; MCS $p = 0.50$). When examined over time, both groups experienced significant improvement in pain, stiffness and function at 1 and 2 years (all $p < 0.001$); however, neither group showed improvement in the SF-36 mental component scores at 1 ($p = 0.36$) and 2 years ($p = 0.93$) postsurgery.

The radiographic results are summarized in Table 1. Whereas t tests comparing alignment angles showed no significant differences (angle A $p = 0.98$; B $p = 0.20$; E $p = 0.97$; F $p = 0.30$), Levene's test showed significant reduction of variance in the flexion-extension alignment of the femoral component ($p = 0.037$) and the varus-valgus alignment of the tibial tray in the FluoroGuide group ($p = 0.026$). The proportion of patients in whom the measured alignment angle was outside of the target range specified by the manufacturer is also presented in Table 1. The proportions of alignment angle deviations were not significantly different between groups (angle A $p = 0.62$; B $p = 0.40$; E $p = 0.14$; F $p = 0.78$).

DISCUSSION

The purpose of our study was to compare a fluoroscopic

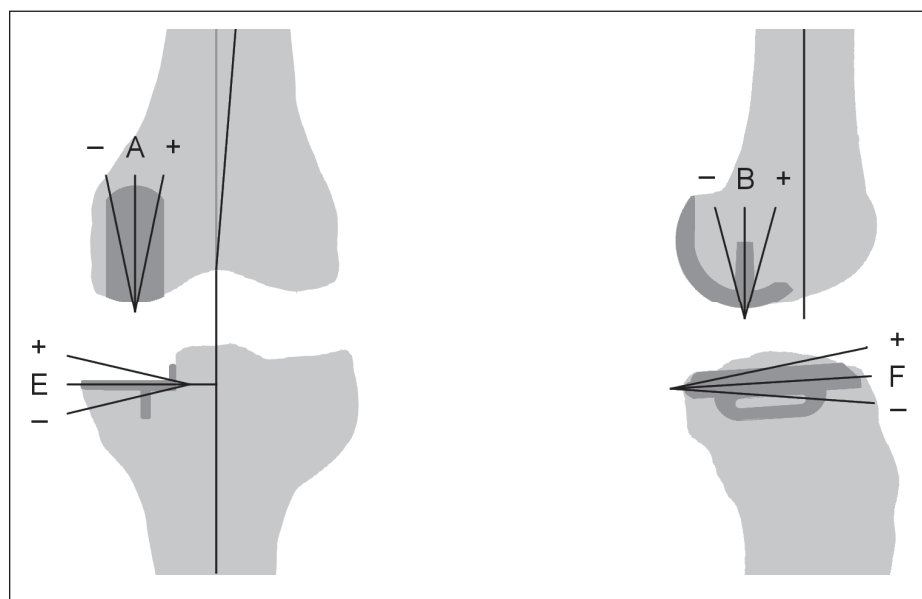


Fig. 3. Measurement of component alignments.⁹

Table 1. Comparison of alignment angles achieved using FluoroGuide versus conventional surgical techniques

Angle	Target angle (range), °	Group; mean (SD) [% outside of target range]			Mean p value / variance	95% CI
		FluoroGuide ($n = 53$)	Conventional ($n = 45$)			
A	-5 (-15 to +5)	-3.8 (6.7) [6]	-3.8 (6.0) [2]	0.98 / 0.70	-2.5 to 2.6	
B	0 (-5 to +10)	2.8 (4.7) [11]	4.2 (6.0) [18]	0.20 / 0.04	-0.8 to 3.6	
E	0 (-5 to +5)	-2.3 (3.8) [15]	-2.2 (5.2) [29]	0.97 / 0.03	-1.2 to 1.9	
F	7 (+2 to +12)	8.0 (2.7) [6]	7.3 (3.8) [4]	0.30 / 0.13	-2.0 to 0.6	

CI = confidence interval; SD = standard deviation.

computer-assisted guidance system to conventional implantation of UKA. We sought to determine whether we would see improvements in implantation accuracy and precision of the femoral component when using a fluoroscopic, computer-assisted technique. This research question was based on the outcome of a previous study that showed the possibility of significant variability in vitro in the implant positioning as a result of the use of the alignment rods provided by the company.³

The main limitation of our study was measured alignment with planar radiographs, which are known to have limited accuracy.¹² We did not use long-film images because the manufacturer's manual of technique defines the range of acceptable alignment parameters based on short-films that do not include the ankle and femoral head. This prevented us from reliably measuring the alignment of the components with respect to the mechanical axis of the leg. Yoshioka and colleagues,¹³ however, reported only a small variation among femora specimens with respect to the angular measures made by the shaft and the long axis. Therefore, we believe our measurement using the anatomic axis of the femur instead of the mechanical axis represents a reasonable measurement of alignment of the lower limb.

We used computer-assisted navigation to perform rotational alignment of the tibial component, but we were unable to measure the rotational alignments of the femoral and tibial components from our radiographs. Measurements of rotational alignment are possible using a technique such as the Perth CT protocol.¹⁴

To date, there is not a vast amount of information available in the orthopaedic literature examining computer navigation in UKA surgery and, to our knowledge, there is no information on the use of fluoroscopic computer-assisted navigation. The following 4 studies, chosen for comparison sake, were not described as randomized clinical trials. Therefore, they are subject to the limitations and biases of observational study designs.

Jenny and Boeri⁵ reported results using a non-image based CAOS system and Depuy Preservation UKA implants. After measuring the coronal and sagittal orientation of both the femoral and tibial components, the authors found there were significantly more patient prostheses in the desired angular range for the computer-assisted versus the noncomputer group. Jenny⁶ conducted the same study using Braun-Aesculap Search prostheses and incorporating a navigated minimally invasive surgery group. Results showed a significant increase in the rate of prostheses implanted in the desired angular range for both navigated groups compared with the conventional surgery group.⁶

Another group of researchers used a CT-free navigation system to analyze the accuracy of postoperative leg alignment and component orientation in patients with Depuy Preservation UKR implants.⁷ Results showed the coronal and sagittal alignment of the tibial component were significantly better for the navigation group. A more recent study

using a Stryker Leibinger navigation system examined the mechanical axis of alignment in the coronal plane using both long-leg weight-bearing films and non-weight bearing computed tomography leg alignment films.⁴ Allegretto (Sulzer) implants were used in the conventional group and EIUS (Stryker-Howmedica) implants in the computer-navigation group. Alignment in the computer-navigation group was determined to be significantly better than the non-navigated group.

In contrast to these studies, we saw no significant differences between groups in regards to the accuracy of all the alignment angles. This could be owing to the limitations stated previously. Another possible reason is that our measurements of the femoral varus–valgus alignment (angle A) were performed relative to the anatomic axis, whereas the computer-assisted navigation was performed relative to the mechanical axis of the femur. There is some variation between individuals in this anatomic–mechanical axis angle,¹³ which would have been reflected in the variance in our measurement of angle A. Finally, the results could be a reflection of no true differences between the 2 surgical groups. More studies with larger samples and better measurement techniques are needed to verify this outcome.

We observed a tendency toward flexed alignment of the femoral component in both groups. This result in the conventional group was consistent with a previous computer-simulation study that demonstrated that the short, thin intramedullary rod introduces a bias toward flexion alignment.³ In the FluoroGuide group, the flexed alignment was probably caused by a tendency to navigate parallel to the posterior aspect of the distal femur instead of the anatomic axis in the sagittal fluoroscopic image. It is easy to acquire a sagittal image that does not include enough of the distal femur to accurately localize the anatomic axis when using the fluoroscopic guidance system.

CONCLUSION

Our study has provided evidence of statistically significant improvement in precision of the femoral flexion–extension alignment (angle B) and the tibial varus–valgus alignment (angle E) when comparing the computer-assisted and the conventional implantation techniques. We did not find significant evidence of improved accuracy when using the fluoroscopic navigation system. In both the FluoroGuide and conventional groups, we found that a high percentage of patients had angles B and E fall outside of the manufacturer's specified ranges of acceptable alignment. Further refinement of the surgical implantation technique is needed.

We have not attempted to correlate the changes in function or longevity that might occur with this technique. The success or failure of the implant is multifactorial; however, it is much more likely that a successful outcome will occur if the components are implanted as prescribed by the

manufacturer in a precise and accurate manner. Given our results, we cannot justify the use of FluoroGuide in its current form over the conventional technique for minimally invasive UKA owing to another level of complexity and systematic error that we are introducing in the operating room with fluoroscopy. If fluoroscopy is to be used, the setup in the operating room needs to be part of the workflow.

Competing interests: None declared for Drs. Ma and Chakraverty and Ms. Grant. Dr. Rudan has received consulting fees from Depuy Orthopaedics as well as speaker fees from Depuy Orthopaedics for talks on computer-assisted surgery.

Contributors: Dr. Rudan designed the study. Drs. Ma and Chakraverty acquired the data, which Drs. Chakraverty and Rudan and Ms. Grant analyzed. Drs. Ma, Chakraverty and Ms. Grant wrote the article, which Dr. Rudan reviewed. All authors approved publication.

References

- Murray DW, Goodfellow JW, O'Connor JJ. The Oxford medial unicompartmental arthroplasty: a ten year survival study. *J Bone Joint Surg Br* 1998;80:983-9.
- Svärd VC, Price AJ. Oxford medial unicompartmental arthroplasty: a survival analysis of an independent series. *J Bone Joint Surg* 2001; 83:191-4.
- Ma B, Long W, Rudan J, et al. Three-dimensional analysis of alignment error in using femoral intramedullary guides in unicompartmental knee arthroplasty. *J Arthroplasty* 2006;21:271-8.
- Cossey AJ, Spriggins AJ. The use of computer-assisted surgical navigation to prevent malalignment in unicompartmental knee arthroplasty. *J Arthroplasty* 2005;20:29-34.
- Jenny J, Boeri C. Unicompartmental knee prosthesis implantation with a non-image-based navigation system: rationale, technique, case-control comparative study with a conventional instrumented implantation. *Knee Surg Sports Traumatol Arthrosc* 2003;11:40-5.
- Jenny JY. Navigated unicompartmental knee replacement. *Orthopedic* 2005;28(10 Suppl):s1263-7.
- Perlick L, Bathis H, Tingart M, et al. Minimally invasive unicompartmental knee replacement with a nonimage-based navigation system. *Int Orthop* 2004;28:193-7.
- Victor J, Hoste D. Image-based computer-assisted total knee arthroplasty leads to lower variability in coronal alignment. *Clin Orthop Relat Res* 2004;428:131-9.
- Goodfellow JW, O'Connor JJ. *The Oxford knee phase 3 unicompartmental knee: manual of surgical technique*. London (UK): Biomet Merck Ltd.; 1999.
- Bellamy N, Buchanan WW, Goldsmith CH, et al. Validation study of WOMAC: a health status instrument for measuring clinically-important patient-relevant outcomes following total hip or knee arthroplasty in osteoarthritis. *J Rheumatol* 1988;15:1833-40.
- Ware JE. The SF-36 health survey. In: Spilker B, editor. *Quality of life and pharmacoeconomics in clinical trials*. 2nd ed. Philadelphia (PA): Lippincott-Raven Publishers; 1996. p 337-45.
- Stulberg SD, Loan P, Sarin V. Computer-assisted navigation in total knee replacement: results of an initial experience in thirty-five patients. *J Bone Joint Surg Am* 2002;84-A:90-8.
- Yoshioka Y, Siu D, Cooke DV. The anatomy and functional axes of the femur. *J Bone Joint Surg Am* 1987;69:873-80.
- Chauhan SK, Clark GW, Lloyd S, et al. Computer-assisted total knee replacement: a controlled cadaver study using a multi-parameter quantitative CT assessment of alignment (the Perth CT protocol). *J Bone Joint Surg Br* 2004;86:818-23.

Canadian Journal of Surgery

Home | Submit a Manuscript | Email Alerts | Issues by Date | About CJS



Readers of *CJS* can subscribe to email alerts to receive the table of contents by email when a new issue appears. Sign up now at cma.ca/cjs.

Les lecteurs du *JCC* peuvent souscrire aux info courriels pour recevoir un avis par courriel pour chaque nouveau numéro. Inscrivez-vous dès maintenant à amc.ca/cjs.