

# Effect of hand packing versus cement gun pressurization on cement mantle in total knee arthroplasty

Michael Kopec, BS  
Joseph C. Milbrandt, PhD  
Todd Duellman, MD  
Doug Mangan, MD  
D. Gordon Allan, MD

From the Division of Orthopedics and Rehabilitation, Southern Illinois University School of Medicine, Springfield, Ill.

Accepted for publication  
Feb. 12, 2009

## Correspondence to:

Dr. J.C. Milbrandt  
Division of Orthopedics and Rehabilitation  
School of Medicine  
Southern Illinois University  
P.O. Box 19679  
Springfield, IL 62794-9679  
fax 217 545-7901  
jmilbrandt@siu.edu

**Background:** Gun pressurization in total knee arthroplasty (TKA) may result in better cement penetration than hand packing, leading to fewer tibial plate failures. We compared cement intrusion characteristics between vacuum mixing and gun pressurization versus hand mixing and packing in the proximal tibia among patients undergoing TKA.

**Methods:** We analyzed 6-week radiographs from 77 consecutive patients for cement area and zone-specific intrusion using computer-assisted image analysis.

**Results:** Penetration into tibial anteroposterior zones 1–6 was not significantly different between the techniques. Intrusion depths in anteroposterior zone 7 and lateral zone 2 were significantly increased with gun pressurization, but this increase was associated with significantly longer operating room and tourniquet times.

**Conclusion:** We identified no obvious advantage of vacuum mixing with gun pressurization, suggesting that continued use of the hand-packing technique may be warranted. Additional long-term failure studies must be completed to compare these techniques.

**Contexte :** Dans l'arthroplastie totale du genou, l'injection du ciment au moyen d'un pistolet à pression permettrait une meilleure pénétration que son application manuelle, et elle donnerait lieu à un taux moindre de descellement au niveau du plateau tibial. Nous avons comparé les caractéristiques d'intrusion du ciment obtenues avec la technique de mélange sous vide et injection sous pression et avec le mélange et l'application manuels au niveau du tibia proximal chez des patients soumis à une arthroplastie totale du genou.

**Méthodes :** À 6 semaines, nous avons procédé à une analyse assistée par ordinateur des clichés radiographiques de 77 patients consécutifs afin d'observer la répartition du ciment et son intrusion spécifique selon les différentes zones.

**Résultats :** Les 2 techniques n'ont pas produit de différences significatives pour ce qui est de la pénétration dans les zones antéropostérieures tibiales 1–6. Les profondeurs d'intrusion dans la zone antéropostérieure 7 et la zone latérale 2 ont été significativement plus grandes avec l'injection sous pression, mais cette augmentation s'est accompagnée d'un allongement substantiel du temps opératoire et de la durée d'application du garrot.

**Conclusion :** Le mélange sous vide avec injection sous pression ne nous a pas semblé conférer d'avantages manifestes. On en déduit qu'il pourrait être justifié de continuer à utiliser la technique d'application manuelle. Il faudra réaliser d'autres études sur les échecs à longue échéance de l'intervention pour comparer adéquatement les 2 techniques.

**A**chieving optimum cement penetration during fixation of the tibial tray component is an essential step in performing a successful total knee arthroplasty (TKA). Cement mantle penetration of 3–5 mm below the tibial base plate has been reported to improve the static strength of the implant–cement–bone construct and to ensure the long-term mechanical fixation of the implant by preventing the infiltration of wear particles, thereby avoiding peripheral osteolysis and associated component loosening.<sup>1–4</sup> Conversely, too much cement penetration can cause thermal necrosis. This is especially a concern in patients with extremely porous bone such as those with rheumatoid arthritis. Multiple techniques have been described to enhance the mechanical properties of the implant–cement–bone construct by controlling

the preparation of the bone surface or cement and the pressure at the cement–bone interface during cementation. Centrifugation and vacuum mixing techniques have been reported to reduce the number of void spaces in the cement, which serve as sites of microcrack initiation,<sup>5–8</sup> but there is some disagreement as to their effectiveness in reducing mean pore size and void fraction.<sup>6</sup> Pulsatile lavage of the bone bed washes away blood marrow and other bone debris, which can improve cement–bone interdigitation.<sup>9–11</sup> Finally, cement pressurization techniques have been developed to increase the depth of cement intrusion into the proximal tibia.<sup>9,12,13</sup> However, use of these devices and techniques are likely to be associated with increased operative time and costs to the institution.

Bauze and colleagues<sup>14</sup> performed a direct comparison of cement penetration using 3 commonly practised cementing techniques (hand packing, surface cementation and cement gun pressurization) in a porcine model. Their findings suggest that the gun injection technique offered a larger area of bone with cement penetration depths greater than 1 mm. In addition, gun injection provided the most consistent elastic modulus and reduced micromotion of the components, suggesting the potential for enhanced long-term fixation. However, clinical concerns regarding whether or not a cement pressurization gun should be used when cementing the tibial component have been reported, as evidenced by a survey of orthopedic surgeons indicating that only 5% were using cement gun pressurization for tibia preparation during TKA.<sup>12</sup>

Cement intrusion depth is thought to be a function of the viscosity of the cement, the permeability of the bone and the pressure gradient applied to the curing methyl methacrylate (MMA). During any TKA, the porosity of the native bone is fixed, and during application of the cement the mean pressure applied should remain quasi-constant. Therefore, controlling the cement viscosity at the time of application to the bone is of great importance to ensure adequate cement intrusion, which leads to the long-term success of the arthroplasty. We designed the present study to determine whether the pressurization afforded by the use of a cement gun significantly increases the cement intrusion depth compared with hand mixing and packing during the cementing of a posterior-stabilized tibial plate.

## METHODS

### *Study population*

We performed a retrospective review and comparison of consecutive patients placed into 2 groups based on the cementation technique used to secure the tibial plate. The first group of consecutive patients underwent TKA with vacuum-mixed and gun-pressurized cementation. They were followed by a second group who underwent TKA cementation using hand mixing and hand packing. The patients included in our study received a TKA procedure

using the same surgical approach and prosthetic components (Zimmer NexGen LPS, Zimmer Inc.), and the same surgeon (D.G.A.) performed all surgeries. The local Institutional Review Board approved our study protocol.

### *Device and cementation technique*

We used Zimmer NexGen LPS Complete Knee System components and Simplex-P bone cement (Stryker Corp.) exclusively for this study. This implant design includes cement wells (indentations) on all cemented component surfaces to facilitate cement capture and retention during the cementing process. We used a tourniquet only at the time of cementing. The procedures were all performed in an ultra-clean room with the surgical team wearing body isolator systems. All polyethylene components were gamma sterilized in nitrogen.

The mixing and application of the polymethyl methacrylate (PMMA) bone cement followed the ASTM F451–99a and ISO 5833–92 standards.<sup>15,16</sup> We prepared the cement in a hand-mixing bowl, where it was mixed for 1 minute and probed every 15 seconds thereafter using a clean Biogel powder-free latex glove.<sup>15,16</sup> When the cement no longer adhered to the glove, we deemed it ready for use. For hand-packed knees, we applied the cement liberally to all surfaces of the prostheses and digitally impacted it into the superior surface of the proximal tibia directly after pulsatile lavage and drying. Additionally, we formed a roughly cylindrical cement mass and placed it in the medullary canal. We then impacted the components into place and carefully removed any cement leaving the immediate space between the bone and prosthesis.

We used the Zimmer vacuum cement mixing system and bone cement injector for all surgeries involving the gun-pressurization procedure. The cement was mixed in a Zimmer vacuum mixer for 1 minute. We used the cement pressurization gun, which was equipped with a straight short barrel nozzle, to apply the cement to the prepared and lavaged tibia. We made a special effort to pressurize the medullary canal of the proximal tibia while placing the gun nozzle at 4 equidistant points from the centre of the medial and lateral halves of the freshly prepared bone bed and applying continuous pressure for about 10 seconds per site. Next, we coated the surfaces of the prosthesis components with cement via the gun and impacted them into place. The surgeon removed any residual cement carefully. The tourniquet was inflated only for bone preparation, pulsatile lavage and cementation of the TKA components. The operating room temperature and humidity set points were 65°F and 55%, respectively, for all procedures.

### *Data collection*

Each patient had physical exams and standard radiographic evaluations at 6 weeks, 6 months and 1 year after the TKA procedure. Outcome evaluations included Knee

Society function (KSSF) and assessment (KSSA) scores and range of motion (ROM) computation and evaluation of the occurrence of radiolucencies. In addition, we collected data from the operative notes for each patient. We also determined patient device status at 3 years post-TKA.

Six weeks postoperatively, we analyzed plain orthogonal radiographs using digitization techniques and MCID Elite 6.0 software (Imaging Research Inc.), calibrated to control for magnification. We analyzed the Knee Society zones on lateral and anteroposterior (AP) radiographs with regard to cement intrusion depth and total area of cement mantle achieved (Fig. 1).<sup>17</sup> We measured the tibial tray height in both the AP and lateral planes to assess the magnification of the radiogram and the rotation of the tray (all trays were 3.5 mm thick) relative to the plane of the film.

**Statistical analysis**

Between-group comparisons of nominal data involved using an unpaired *t* test or 1-way analysis of variance (ANOVA), and we compared categorical data using a  $\chi^2$  test. We performed all comparisons using GraphPad Prism version 4.03 (GraphPad Software Inc.). Based on an assumed standard deviation (SD) of 1.8 mm per group and 41 knees per group, our study had 80% power to detect a difference between means of 1.0 mm with a significance level ( $\alpha$ ) of 0.05 (1-tailed).

**RESULTS**

We identified 39 consecutive patients (41 knees) who had a TKA with vacuum-mixed and gun-pressurized Simplex-P bone cement for inclusion in our study. We also identified 38 consecutive patients (41 knees) who underwent TKA with a hand mixing and packing cementation technique for inclusion. Group demographics are shown in Table 1. We observed no statistically significant differences between the groups for age ( $p = 0.07$ ), sex ( $p = 0.94$ ) or tibial component size ( $p = 0.50$ ). The mean operating room time (67.3 v. 75.9 min,  $p = 0.013$ ) and tourniquet time (23.5 v. 27.9 min,  $p = 0.018$ ) were significantly shorter for the hand-packing

group compared with the gun-pressurization group (Table 1).

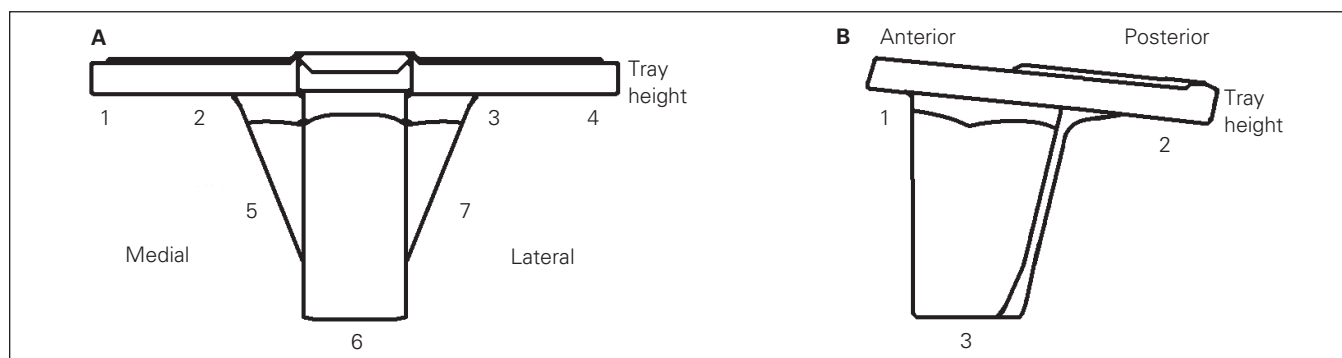
Radiographic image analysis at 6 weeks of the Knee Society zones (Fig. 1) in the AP and lateral planes revealed that all zones were above the 3-mm threshold commonly reported to give good clinical results.<sup>4,18</sup> Penetration into tibial anteroposterior zones 1–6 was not significantly different between the techniques. The depth of cement penetration in the AP radiographic plane was higher in zones 1–5 and 7 of the tibial plateau with the gun-pressurization technique, but this increase was only statistically significant in zone 7 (Fig. 2). We observed a significant increase in cement depth penetration in the lateral radiographic plane zone 2 at 6 weeks for the gun-pressurization group compared with the hand-packing group (Fig. 3). When the entire cement mantle was measured, both the AP and lateral radiographic areas showed a clear increase in the gun pressurization group compared with the hand-packing group (Fig. 4).

We detected no statistically significant differences in

**Table 1. Demographic and clinical characteristics of 77 consecutive patients who underwent total knee arthroplasty using the gun-pressurization or hand-packing techniques**

Characteristic	Cementing method, mean (SD)*		<i>p</i> value
	Gun pressurization	Hand packing	
Patients, no.	39	38	
Knees, no.	41	41	
Age, yr	64.2 (12.3)	69.3 (12.8)	0.07
Sex, % female	69.2	68.4	0.94
Tibial plate size, mm	5	5	0.50
Operating room time, min	75.9 (18.2)	67.3 (11.8)	0.013
Tourniquet time, min	27.9 (10.6)	23.5 (4.1)	0.018
Preoperative functional assessment			
HSS	61.4 (11.0)	58.0 (12.0)	0.20
KSSF	44.5 (16.5)	48.6 (16.7)	0.27
KSSA	40.8 (16.9)	34.2 (16.8)	0.09
ROM	103.0 (14.5)	99.6 (22.4)	0.42

HSS = Hospital for Specialty Surgery score; KSSA = Knee Society score, assessment; KSSF = Knee Society score, function; ROM = range of motion; SD = standard deviation.  
\*Unless otherwise indicated.

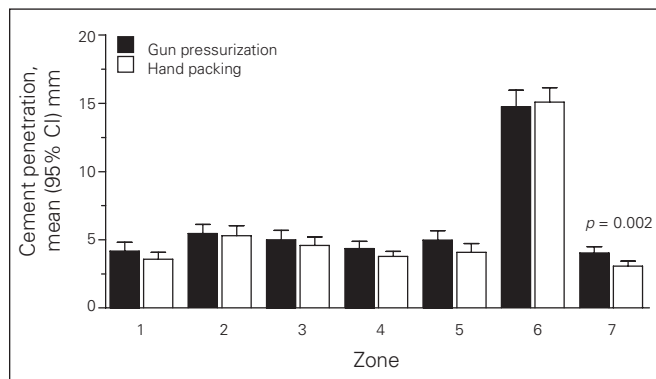


**Fig. 1.** At 6 weeks, cement mantle depth penetration measurements were made in the zones numbered in the anteroposterior and lateral views of the tibial tray. The total area of cement mantle was also assessed from the radiographs.

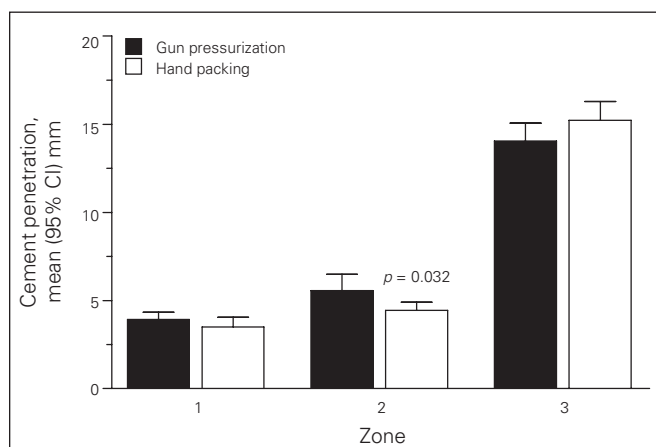
postoperative knee scores, functional assessments (Hospital for Specialty Surgery score [HSS], KSSSA and KSSF scores and ROM) between the 2 groups at 6 weeks, 6 months or 1 year (Table 2). At 1 year, we identified 2 tibial radiolucencies in the gun-pressurization group ( $n = 33$ , 6%) and 1 radiolucency in the hand-packing group ( $n = 30$ , 3.3%). At 3 years, no device-related failures or revisions were identified in either the gun-pressurization group ( $n = 34$ ) or the hand-packing group ( $n = 28$ ). Potential procedure-related adverse events identified during the follow-up period included 1 instance of deep vein thrombosis and 1 instance of superficial infection. In addition, 1 patient had patellofemoral crepitus and 1 had arthrofibrosis, both of which were treated with arthroscopy.

**DISCUSSION**

The desired cement mantle for optimum fixation of the tibial tray during a TKA has been reported to be 3–5 mm,<sup>1,2</sup>

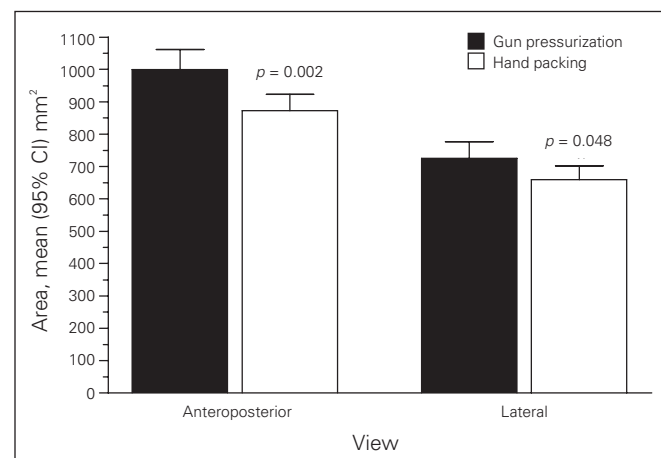


**Fig. 2.** Depth of cement penetration in the anteroposterior radiographic plane is compared between cementation techniques at 6 weeks ( $n = 41$  knees per group). Cement intrusion depth was higher in zones 1–5 and 7 of the tibial plateau with the gun-injection technique, but this increase was only statistically significant in zone 7. CI = confidence interval.



**Fig. 3.** Depth of cement penetration in the lateral radiographic plane between cementation techniques at 6 weeks ( $n = 41$  knees per group). Cement penetration after gun pressurization was significantly increased in zone 2. CI = confidence interval.

with a recent report suggesting 4–10 mm may be ideal.<sup>19</sup> With the interface pressures created by this particular implant type (Zimmer LPS) and cementation technique (pulsatile lavage and drying), use of a cement pressurization gun did not significantly increase the cement penetration depth in AP zones 1–4 of the tibial plateau. The incidence of radiolucencies at 1-year follow-up was also similar between techniques. Increasing the cement intrusion depth without increasing cement porosity or sacrificing the prosthesis–cement interface quality is thought to reduce micromotion and improve the fatigue life of the arthroplasty.<sup>20</sup> However, since the mean difference in penetration depth in zones located along the tibial plateau in the AP



**Fig. 4.** The area of cement penetration in the anteroposterior and lateral radiographic planes between cementation techniques at 6 weeks ( $n = 41$  knees per group) was significantly increased with the gun-pressurization procedure. CI = confidence interval.

**Table 2. Change between the pre- and postoperative functional assessments of 77 consecutive patients who underwent total knee arthroplasty using either the gun-pressurization or hand-packing technique**

Change in functional assessment, follow-up	Cementing method, mean (SD)		p value
	Gun pressurization	Hand packing	
<b>HSS</b>			
6 wk	5.5 (14.6)	7.8 (15.3)	0.50
6 mo	19.0 (10.9)	18.6 (14.8)	0.90
1 yr	21.0 (10.7)	19.4 (11.1)	0.55
<b>KSSF</b>			
6 wk	-4.2 (17.9)	4.9 (22.1)	0.05
6 mo	15.3 (20.3)	20.8 (24.7)	0.31
1 yr	21.3 (24.7)	19.2 (17.0)	0.70
<b>KSSA</b>			
6 wk	33.1 (23.6)	35.2 (21.8)	0.69
6 mo	46.0 (20.4)	41.3 (21.8)	0.36
1 yr	42.4 (22.6)	43.2 (21.6)	0.87
<b>ROM</b>			
6 wk	-1.2 (20.6)	-3.2 (19.5)	0.67
6 mo	10.4 (18.2)	8.3 (17.7)	0.63
1 yr	6.1 (18.6)	11.3 (15.2)	0.22

HSS = Hospital for Specialty Surgery score; KSSA = Knee Society score, assessment; KSSF = Knee Society score, function; ROM = range of motion; SD = standard deviation.



plane was only 0.4 mm, and since both penetration depth values are above the threshold reported to give good clinical outcomes in all zones, it appears that either technique provides adequate cement intrusion in these areas.

Lutz and colleagues<sup>19</sup> reported significantly greater depths of cement penetration when using gun pressurization or syringe application versus cement application by hand. They reported a nearly 2-fold increase or larger in the measured cement depth when using gun pressurization in each zone examined in their study (AP zones 1 and 4 and lateral zones 1 and 2).<sup>19</sup> The observed differences in cement depth ranged between 1.9 and 3.7 mm.<sup>19</sup> Our findings confirm a general increase in cement depth when using gun pressurization; however, they do not approach the observed differences compared with hand packing, as previously reported.<sup>19</sup> The larger differences in that study could be attributed to the use of a standard-viscosity cement (CMW-I; Depuy) in the hand-application group versus a low-viscosity cement (Antibiotic Simplex; Stryker/Howmedica) for the gun-pressurization group.<sup>19</sup> It is also possible that the use of a different TKA prosthetic and/or surgeon technique could account for the smaller differences observed in our study.

There is some debate as to whether full cementation of the tibial component is advantageous from a mechanical perspective, and our results indicate that the regions where the gun-pressurization technique increases penetration depth are located in zones that may not be as highly stressed.<sup>20</sup> Since satisfactory clinical results have been reported for the cement intrusion depth range that we observed and since radiolucency incidence was similar in both groups, we feel that continued use of the hand-packing technique is warranted at this time.<sup>4,18</sup>

## CONCLUSION

Although cement penetration was generally higher when using vacuum mixing and gun pressurization, we identified no obvious clinical advantage over hand mixing and packing. The cement-pressurization system enables increased interface pressures, which in turn increases cement intrusion depth.<sup>21</sup> However, the relatively small increase observed in cement intrusion associated with gun pressurization in our study came at the expense of longer operating room and tourniquet times and the additional expense of a gun-pressurization system. Although we observed no clinical signs of tibial plate loosening in either group at 1 year and the device survival at 3 years is 100%, additional long-term evaluation is critical to assess whether the increased cement intrusion using gun pressurization leads to a reduction in device failure rates.

**Acknowledgement:** We thank the Southern Illinois University School of Medicine Department of Surgery and Division of Orthopedics for the partial support of this project.

**Competing interests:** The authors receive funding from the device manufacturer for other sponsored clinical trials. Dr. Allan owns stock in the device manufacturer.

**Contributors:** Drs. Kopec, Duellman, Mangan and Allan designed the study. Drs. Kopec, Duellman and Mangan acquired the data, which Drs. Millbrandt, Duellman and Mangan analyzed. All authors participated in writing the article, which Dr. Allan reviewed. All authors approved publication.

## References

- Mann KA, Ayers DC, Werner FW, et al. Tensile strength of the cement-bone interface depends on the amount of bone interdigitated with PMMA cement. *J Biomech* 1997;30:339-46.
- Norton MR, Eyres KS. Irrigation and suction technique to ensure reliable cement penetration for total knee arthroplasty. *J Arthroplasty* 2000;15:468-74.
- Dorr LD, Lindberg JP, Claude-Faugere M, et al. Factors influencing the intrusion of methylmethacrylate into human tibiae. *Clin Orthop Relat Res* 1984;183:147-52.
- Walker PS, Soudry M, Ewald FC, et al. Control of cement penetration in total knee arthroplasty. *Clin Orthop Relat Res* 1984;185:155-64.
- Klein RW, Scott CP, Higham PA. The strength of acrylic bone cement cured under thumb pressure. *Biomaterials* 2004;25:943-7.
- Macaulay W, DiGiovanni CW, Restrepo A, et al. Differences in bone-cement porosity by vacuum mixing, centrifugation, and hand mixing. *J Arthroplasty* 2002;17:569-75.
- Wilkinson JM, Eveleigh R, Hamer AJ, et al. Effect of mixing technique on the properties of acrylic bone-cement: a comparison of syringe and bowl mixing systems. *J Arthroplasty* 2000;15:663-7.
- Hahn M, Engelbrecht E, Delling G. [A quantitative analysis for determining porosity of pre-compressed and vacuum-mixed bone cement] [Article in German]. *Chirurg* 1990;61:512-7.
- Stannage K, Shakespeare D, Bulsara M. Suction technique to improve cement penetration under the tibial component in total knee arthroplasty. *Knee* 2003;10:67-73.
- Majkowski RS, Miles AW, Bannister GC, et al. Bone surface preparation in cemented joint replacement. *J Bone Joint Surg Br* 1993;75:459-63.
- Majkowski RS, Bannister GC, Miles AW. The effect of bleeding on the cement-bone interface. An experimental study. *Clin Orthop Relat Res* 1994;299:293-7.
- Lutz MJ, Halliday BR. Survey of current cementing techniques in total knee replacement. *ANZ J Surg* 2002;72:437-9.
- Labutti RS, Bayers-Thering M, Krackow KA. Enhancing femoral cement fixation in total knee arthroplasty. *J Arthroplasty* 2003;18:979-83.
- Bauze AJ, Costi JJ, Stavrou P, et al. Cement penetration and stiffness of the cement-bone composite in the proximal tibia in a porcine model. *J Orthop Surg (Hong Kong)* 2004;12:194-8.
- ASTM F 451-99a. *Standard specification for acrylic bone cement*. Available: [www.astm.org/Standards/F451.htm](http://www.astm.org/Standards/F451.htm) (accessed 2009 Sept. 30).
- International Standard ISO 5833:2002. *Implant for surgery-acrylic resin cements*. Available: [www.iso.org/iso/iso\\_catalogue/catalogue\\_ics/catalogue\\_detail\\_ics.htm?csnumber=30980](http://www.iso.org/iso/iso_catalogue/catalogue_ics/catalogue_detail_ics.htm?csnumber=30980) (accessed 2009 Sept. 30).
- Ewald FC. The Knee Society total knee arthroplasty roentgenographic evaluation and scoring system. *Clin Orthop Relat Res* 1989;248:9-12.
- Kim YH, Walker PS, Deland JT. A cement impactor for uniform cement penetration in the upper tibia. *Clin Orthop Relat Res* 1984; (182):206-10.
- Lutz MJ, Pincus PF, Whitehouse SL, et al. The effect of cement gun and cement syringe use on the tibial cement mantle in total knee arthroplasty. *J Arthroplasty* 2008; epub ahead of print.
- Peters CL, Craig MA, Mohr RA, et al. Tibial component fixation with cement: full- versus surface-cementation techniques. *Clin Orthop Relat Res* 2003; (409):158-68.
- Baroud G, Wu JZ, Bohner M, et al. How to determine the permeability for cement infiltration of osteoporotic cancellous bone. *Med Eng Phys* 2003;25:283-8.