Managing complications associated with laparoscopic Roux-en-Y gastric bypass for morbid obesity

P. Sahle Griffith, MBBS MRCS DM*
Daniel W. Birch, MSc MD*
Arya M. Sharma, MD PhD†
Shahzeer Karmali, MD*

From the *Department of Surgery and the †Department of Medicine, University of Alberta, Edmonton, Alta.

Accepted for publication
Dec. 5, 2011

Correspondence to:
S. Karmali
405 CSC 10240 Kingsway Ave.
Edmonton AB T5H 3V9
shahzeer@ualberta.ca

DOI: 10.1503/cjs.002011

Obesity has become a major health concern in Canada. This has resulted in a steady rise in the number of bariatric surgical procedures being performed nationwide. The laparoscopic Roux-en-Y gastric bypass (LRYGB) is not only the most common bariatric procedure, but also the gold standard to which all others are compared. With this in mind, it is imperative that all gastrointestinal surgeons understand the LRYGB and have a working knowledge of the common postoperative complications and their management. Early postoperative complications following LRYGB that demand immediate recognition include anastomotic or staple line leak, postoperative hemorrhage, bowel obstruction and incorrect Roux limb reconstructions. Later complications may be challenging to differentiate from other gastrointestinal disorders and include anastomotic stricture, marginal ulceration, fistula formation, weight gain and nutritional deficiencies. We discuss the principles involved in the management of each complication and the timing of referral to specialist bariatric centres.

L'obésité est devenue un problème de santé majeur au Canada. Le phénomène est à l'origine d'une augmentation constante du nombre de chirurgies bariatriques effectuées partout au pays. La dérivation gastrique laparoscopique Roux-en-Y n'est pas seulement la technique bariatrique la plus courante, elle est aussi la norme à laquelle toutes les autres se comparent. Compte tenu de cela, il est crucial que tous les spécialistes en chirurgie digestive comprennent cette intervention et aient une connaissance pratique de ses complications postopératoires fréquentes et de leur prise en charge. Les complications postopératoires immédiates de cette technique qu'il faut reconnaître sans tarder incluent : la fuite anastomotique (le long de la ligne d'agrafes), l'hémorragie postopératoire, l'obstruction intestinale et les reconstructions incorrectes de la branche Roux. Les complications tardives peuvent être difficiles à distinguer des autres troubles gastro-intestinaux et comprennent, notamment : la sténose anastomotique, l'ulcération marginale, la formation de fistules, l'échec de la perte pondérale et certains déficits nutritionnels. Nous discutons ici les principes qui sous-tendent la prise en charge de chaque complication et le moment où il est indiqué d'adresser les patients vers des centres spécialisés en soins bariatriques.

Obesity has become a major health concern in Canada,[1] with extreme obesity increasing in prevalence across the country by more than 400% in the last 2 decades.[2] Given the rise in obesity rates, the need to increase the capacity to perform bariatric surgery has become a focus of provincial planners. This is reflected in a steady rise in the number of procedures being performed nationwide, with statistical data revealing a 63% increase in the volume of inpatient bariatric procedures performed across Canada in 2008–2009 compared with 2004–2005.[3] Whereas there has been evidence to suggest that increased surgical volumes impact positively on survival outcomes,[4] data to date have been unable to clearly demonstrate superior outcomes with regards to readmissions, reoperations and mortality in bariatric surgical centres of excellence relative to other surgical facilities.[5]

There are various surgical options available for the management of morbid obesity. These vary from purely restrictive procedures, such as the laparoscopic adjustable gastric band, to purely malabsorptive procedures, such as the jejunoileal bypass. In an attempt to reduce the complications associated with purely malabsorptive procedures while still improving on the weight loss and comorbidity resolution of the purely restrictive procedures, a number of

hybrid restrictive/malabsorptive procedures have been developed. These include the laparoscopic Roux-en-Y gastric bypass (LRYGB), the biliopancreatic diversion and the duodenal switch. Of these, the LRYGB has become the gold standard bariatric procedure to which all others are compared[6] and accounts for about 70% of all bariatric surgeries performed worldwide.[7]

With this in mind, it is therefore prudent that surgeons performing bariatric procedures, as well as the general surgical community as a whole, become aware of the potential complications that can arise from LRYGB and take a rational approach to managing these complications. This review discusses the major perioperative (< 2 wk postoperative) and late complications that can arise in patients who have undergone LRYGB. Emphasis is placed on the principles involved in the management of each complication and the timing of referral to specialist bariatric centres.

Discussion

Gastric bypass was first used in the management of morbid obesity by Mason and Ito in 1966.[8] Over the last 4 decades, as laparoscopic expertise has improved, gastric bypass has evolved into the laparoscopic version generally performed today. The procedure involves construction of a 15–30 mL proximal gastric pouch based on the lesser curvature of the stomach, created by dividing the stomach with endovascular staplers around a bougie (ranging in size from 32 to 50 Fr). The jejunum is then divided at a point 25–50 cm from the ligament of Trietz, and the distal alimentary limb is mobilized either in a retrocolic or antecolic fashion and anastomosed to the gastric pouch. The biliopancreatic limb of the jejunum is then anastomosed to the alimentary limb between 100 and 150 cm from the gastrojejunostomy (Fig. 1).

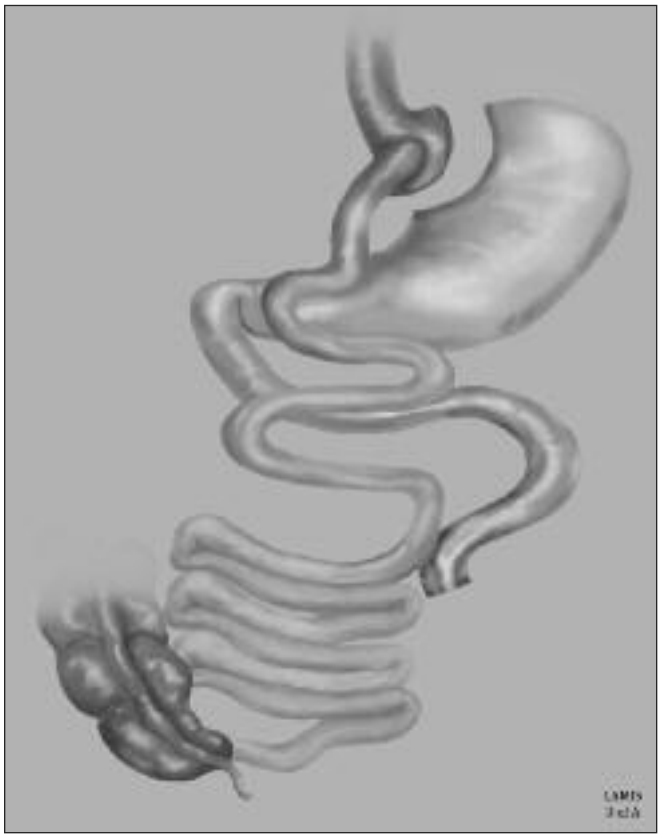

Fig. 1. Anatomy of a Roux-en-Y gastric bypass.

Postoperative complications following LRYGB can be broadly grouped into early and late complications. By definition, early complications occur within the immediate perioperative period — the first 2 weeks post-LRYGB. Late complications arise after the second postoperative week. Medical complications, such as deep vein thromboses, pulmonary embolism and myocardial infarctions can occur following any operative intervention. However, these are remarkably infrequent following bariatric surgery and often serve only to distract the surgical team from making an early diagnosis of a surgical complication. The early complications we focus on here are those directly linked to LRYGB. These include anastomotic or staple line leak (ASL), postoperative hemorrhage, bowel obstruction and incorrect Roux limb reconstructions.

Early complications

Anastomotic or staple line leaks

Anastomotic or staple line leaks are the most dreaded and potentially devastating complication of this procedure,[9] with a mortality rate of nearly 50%.[9,10] A multivariate logistic regression analysis in a study that included more than 3000 patients who underwent LRYGB concluded that ASL was one of the strongest independent risk factors for postoperative death.[11] Fortunately, the incidence of ASL is relatively low at 0.4%–5.2%.[11–15] It is pertinent, however, to mention that experience performing LRYGB plays an important role in lowering the ASL rate, with large retrospective series revealing an almost 40% reduction in ASL as the surgeons became more adept using the technique.[9] To this end, as more surgeons across Canada begin to perform LRYGB, appropriate training, mentorship and meticulous adherence to the details of the operative technique will be important in maintaining a low ASL rate.[14]

Anastomotic leaks occur most frequently at the gastrojejunal anastomosis[12,16] (Fig. 2); therefore, most bariatric surgeons use some method for intraoperatively testing the integrity of this anastomosis, either via instillation of methylene blue (Fig. 3) through an orogastric tube or insufflation of air via an orogastric tube or flexible gastroscope with the anastomosis submerged.[9,12–15]

Early recognition of ASL is critical to avoid further adverse outcomes.[9] Unfortunately, a certain degree of experience is necessary to make this challenging diagnosis. The diagnosis of ASL is typically based on clinical grounds, with or without the help of radiographic studies.[10,13]

Clinical signs, such as tachycardia, pyrexia, abdominal pain, purulent drain output, oliguria and nausea or vomiting, are harbingers of ASL.[9,13,16,17] A recent study concluded that sustained tachycardia with a heart rate in excess of 120 beats per minute was a good indicator of an ASL.[13] The necessity of routine upper gastrointestinal (UGI) contrast studies has been questioned by some groups;[18–20] however, such routine testing within the first 24–36 hours postoperatively has been standard practice among many bariatric surgeons.[13–15]

Early operative management is the mainstay of treatment for ASLs following LRYGB. The operative goals are to confirm and repair the ASL, remove GI contents from the abdominal cavity and place closed suction drains.[16] It should be noted that, often, repair of the ASL may be challenging, as the acutely inflamed tissues might not be amenable to suture placement. In such cases, the removal of GI contents and prudent placement of drainage tubes may be the safest option. Placement of a feeding gastrostomy into the gastric remnant or a feeding jejunostomy could also be considered, as this would allow for continued enteral nutrition while bowel rest is maintained at the site of the ASL.

A laparosopic or open approach to the management of ASLs may be used depending on the skill and expertise of the surgeon. More recently, owing to the use of closed suction drains in the region of the gastrojejunal anastomosis, some surgeons are now willing to manage ASLs nonoperatively provided certain criteria, including the absence of sepsis or hemodynamic instability, are met. The mainstay of this treatment involves the use of intravenous antibiotics, monitoring of secretions through the drains and nasoenteral nutrition. This approach has been shown to be successful and lacks the morbidity associated with a reoperation.[9,12] It should be noted that this approach represents a deviation from standard protocol and should only be attempted at specialist bariatric centres with vast experience in the postoperative management of patients who have undergone LRYGB. To this end, we recommend that all patients in whom an ASL is suspected should be returned to theatre promptly to facilitate an operative exploration.

Fig. 2. Leak of the staple line at the gastrojejunostomy.

Postoperative hemorrhage

Postoperative bleeding is a serious early complication following LRYGB. In a systematic review comparing open versus laparoscopic RYGB, it was noted that the frequency of GI tract hemorrhage was significantly higher in the LRYGB series,[21] and the literature reports an incidence between 1.9% and 4.4%.[7,13,21–23]

There are 2 types of postoperative hemorrhage noted to occur following LRYGB. The first is bleeding into the abdominal cavity (intra-abdominal), possibly from staple lines at the gastrojejunostomy, the gastric pouch, the jejunojejunostomy or the excluded stomach.[23] The second source of bleeding is intraluminal at the aforementioned sites. As has been mentioned previously, drains are sometimes left following LRYGB. Some groups have suggested that their primary role is to allow the early diagnosis of postoperative hemorrhage and to distinguish this from an ASL.[7] However, as in other areas of GI surgery, drains are not always a reliable indicator, particularly in the case of intraluminal bleeding. Therefore, once again, a heavy reliance on clinical parameters and laboratory work-up become most important. Features such as a large quantity of bloody fluid from the abdominal drains, tachycardia, a drop in the hemoglobin level, bright red blood per rectum, hematemesis and melena have been found to indicate postoperative hemorrhage.[13]

In patients with substantial postoperative hemorrhage, abdominal re-exploration using either a laparoscopic or open approach must be performed. The operative goals are to evacuate the majority of the clots, attempt to identify and control the site of hemorrhage if it is readily apparent[13] or

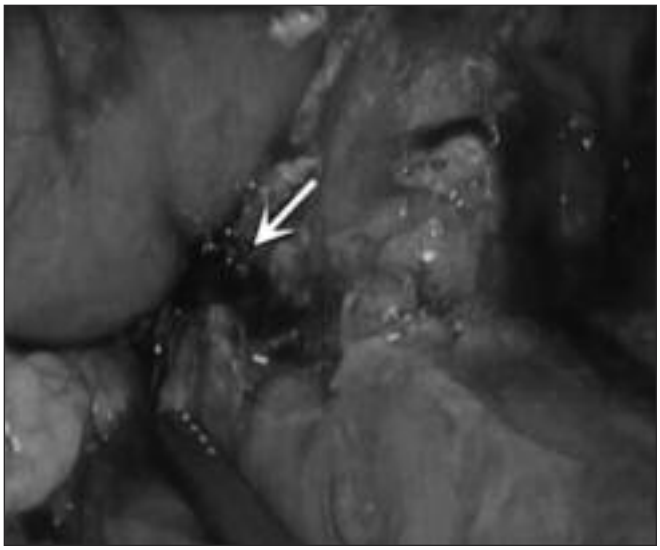

Fig. 3. Methylene blue leaking through gastrojejunal anastomosis during intraoperative testing.

to oversew all staple lines if the patient is hemodynamically unstable and does not have an obvious bleeding point.[23]

Small bowel obstruction

The most common causes of small bowel obstruction following LRYGB are related to internal hernias. As outlined earlier, LRYGB can be accomplished using either an antecolic or retrocolic approach. As such, a number of potential mesenteric defects are created. The retrocolic approach creates 3 such defects: one in the transverse mesocolon, one at the site of the jejunojejunostomy and a Petersen defect (a space created between the Roux limb and the transverse mesocolon). The antecolic approach creates only 2 mesenteric defects: one at the jejunojejunostomy and a Petersen defect.

The time interval between the LRYGB and the onset of symptoms related to an internal hernia is highly variable.[24] Long-term follow-up of patients after LRYGB reveals that internal hernia becomes the most common complication over time,[25] with an incidence ranging from 1% to 9%.[24–27] In addition, it has been noted that while this complication was relatively rare during the era of open RYGB, it is more frequent following LRYGB.[24]

A number of hypotheses have been put forward to explain this phenomenon. Some groups suggested that the reduced bowel manipulation and peritoneal irritation with the laparoscopic approach caused fewer postoperative adhesions and thus resulted in reduced fixation of the Roux limb and less scarring to help close mesenteric defects.[24] Furthermore, rapid excess weight loss following LRYGB leads to increased risk of internal hernia.[25] Inadequate closure of mesenteric defects has also been incriminated as a causative factor, with various groups advocating the meticulous closure of all possible defects with running, nonabsorbable suture as a means of reducing the rate of this complication.[24,26,27] Finally, it has also been debated whether retrocolic approaches with the additional defect contribute to an increased incidence of internal hernia, with some authors suggesting that an antecolic approach reduces the incidence of this complication.[27]

Ultimately, regardless of the cause or site, internal hernias can pose a life-threatening risk to patients who have undergone gastric bypass owing to the possibility of strangulation and perforation of bowel loops trapped within the hernia. This being said, internal hernias are difficult to diagnose clinically or with radiographic imaging.[27] The symptoms are typically episodic and can range from innocuous intermittent, colicky periumbilical pain and nausea to vomiting, anorexia and abdominal distension to dramatic acute presentations of peritonitis and septic shock.[24,28]

To avoid delays in diagnosis producing catastrophic results, a high index of suspicion for the presence of internal hernias must be maintained in patients who have undergone gastric bypass and report episodic abdominal pain. Therefore, these patients are frequently investigated with contrast small bowel series and/or computed tomography (CT). It should, however, be remembered that spontaneous reduction of the hernia can occur, and so a large percentage of these patients will have normal imaging results,[24] leading some authors to deem these investigations noncontributory to the diagnosis.[28] However, our team has identified whorling of the small bowel mesentery, the presence of the cecum and terminal ileum in the right upper quadrant of the abdomen and the existence of the majority of the small bowel loops on one side of the abdominal cavity as a triad of CT scan findings that seem to be pathognomonic for the presence of an internal hernia (Fig. 4). Ultimately, in any patient suspected of having an internal hernia there should be a low threshold for surgical exploration. Typically, as there are commonly few adhesions, the procedure can frequently be completed laparoscopically (Fig. 5). As such, if the requisite laparoscopic expertise is unavailable at the institution where the patient presents, the possibility of transfer to a specialist centre must be entertained. Finally, most groups recommend closing these defects with a continuous nonabsorbable suture, as this has been shown to result in a reduced initial hernia rate.[24,25,27,28]

Another rare but potentially devastating complication of LRYGB involves the inadvertent anastomosis of the proximal biliopancreatic limb of the jejunum to the gastric pouch in conjunction with a misplaced jejunojejunostomy. This so called Roux-en-O construction gives rise to a blind loop. Although this seems to be an atypical complication infrequently reported in the literature, we discuss it here because it can be easily avoided, and if it does occur, it poses unique diagnostic challenges and profoundly increases patient morbidity.[29]

Patients with the Roux-en-O configuration typically present with abdominal pain, biliary emesis, esophagitis and

Fig. 4. Computed tomography scan showing pathognomonic internal hernia findings. The white arrow points to whorling of the mesentery. The black arrow points to majority of small bowel on the left side of the abdomen, and the "X" marks the position of the terminal ileum/cecal junction.

severe dehydration. This occurs quite early in the postoperative period. In reviewing the published case reports on this complication, Sherman and colleagues[29] noted there was a quite protracted wait between the patient's initial presentation and the time at which the diagnosis was determined. This period was filled with numerous contrast radiologic studies and endoscopies, which commonly failed to highlight any important pathology. Ultimately, it seems as though only hepatobiliary iminodiacetic acid (HIDA) scanning was able to facilitate the diagnosis of the complication accurately by revealing prompt reflux of radioactive tracer from the duodenum to the esophagus. Each of the patients in the review had undergone repeated operative interventions, numerous complications, protracted hospital admissions and severe delay in the commencement of oral intake.

The best management strategy for this problem is to avoid creating the Roux-en-O anastomosis at the initial surgery. Sherman and colleagues[29] suggested that a lack of surgical experience with bariatric techniques may be the most important predisposing factor to this complication. To this end, they proposed that the biliopancreatic limb be made no longer than 50 cm, thus precluding its easy anastomosis to the gastric pouch. Furthermore, the Roux limb should be marked with a suture, short segment Penrose drain or Weck clip promptly after the jejunum is divided to facilitate easy differentiation between itself and the biliopancreatic limb. Finally, before fashioning the jejunojejunostomy, the biliopancreatic limb should be traced back to the ligament of Trietz so that proper orientation is assured. If intraoperative detection of a Roux-en-O was missed and a patient presents postoperatively with suspicious symptoms and little radiographic evidence of pathology, a HIDA scan should be obtained before surgical intervention to help with diagnosis, as the aberrant construction is sometimes hard to detect intraoperatively in a hostile abdomen.

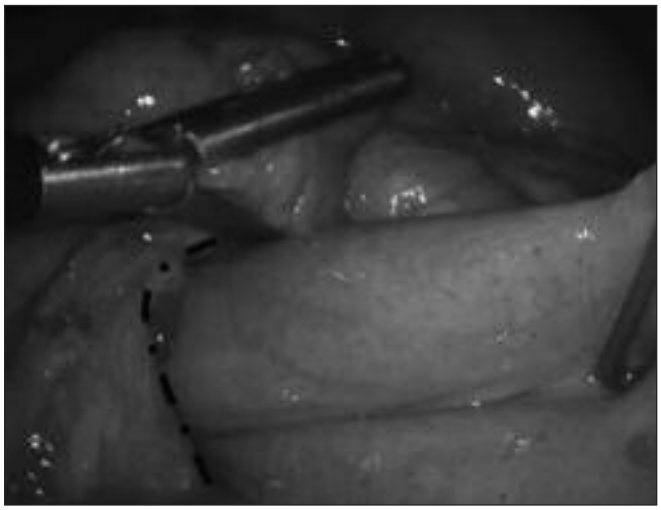

Fig. 5. Small bowel herniating through a Petersen defect. The transverse mesocolon is marked by the dashed line.

Late complications

Aside from the formation of internal hernias, a range of other complications can develop over the long term in patients who have undergone LRYGB. These complications include anastomotic stricture, marginal ulcer formation, fistula formation, weight gain and nutritional deficiencies.

Gastrojejunostomy anastomotic stricture

Stricture of the gastrojejunal anastomosis represents a well-described, long-term complication of RYGB[30] (Fig. 6), with a documented incidence ranging from 2.9% to 23.0% of patients.[31,32] Factors affecting the development of anastomotic strictures include tension or ischemia at the anastomosis and the healing capacity of individual patients.[30,33] It has been noted that this complication is substantially more frequent with the laparoscopic than the open approach.[32] Whether this is because of the frequency of a hand-sewn technique in open RYGB compared with the prevalence of the stapled technique in the laparoscopic era is the subject of debate.[34] However, it has been shown that the incidence of gastrojejunostomy anastomotic stricture may be higher when a 21 mm versus a 25 mm circular stapler is used in construction of the gastrojejunostomy.[31,33]

Patients with gastrojejunostomy anastomotic stricture may present weeks to months postoperatively with progressive dysphagia and daily vomiting associated with little or no abdominal pain.[30] Typically, radiographic studies appear to have poor specificity for the diagnosis of gastrojejunostomy anastomotic stricture, so a UGI endoscopy should be performed in all suspected cases.[32] Fortunately, the endoscopic approach of pneumatic dilatation of the strictures is frequently successful in managing these patients[30–34] (Fig. 6).

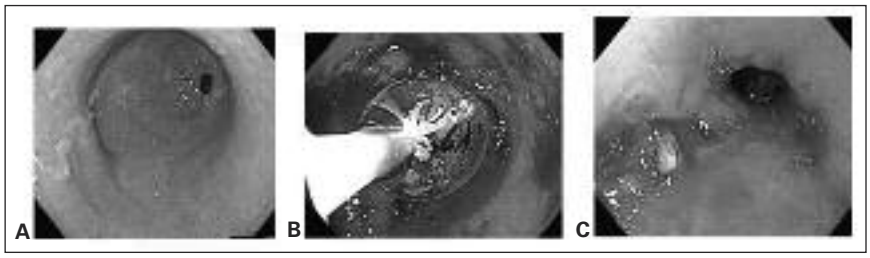

Fig. 6. Endoscopic view of (**A**) gastrojejunal anastomotic stricture, (**B**) balloon dilatation of stricture and (**C**) postdilatation.

However, in the rare instance of failure of the endoscopic technique, an operative approach may be justified.

Marginal ulceration

Marginal ulceration is an important complication of LRYGB. It corresponds to a peptic ulcer at the jejunal mucosa near the site of the gastrojejunal anastomosis and occurs in 1%–16% of patients.[35,36] Whereas the exact etiology of these lesions is unclear,[37] hypotheses have ranged from the size of the gastric pouch to ischemia and the presence of a foreign body at the anastomosis.[35] Recently, it has been shown that the presence of a *Helicobacter pylori* infection preoperatively may correlate with the development of a marginal ulceration in the postoperative period,[37] possibly suggesting a causative role for this organism.

In patients with a marginal ulcer, epigastric pain is the most common presenting symptom and is frequently the only symptom. However, patients may present with nausea and vomiting or bleeding from their ulcers. Endoscopy is often diagnostic, and typically the ulcers heal after a course of proton pump inhibitors and sucralfate.[36,37] If this approach is unsuccessful and a gastrogastric fistula is excluded, biopsy of the gastric pouch may be necessary to rule out the presence of an *H. pylori* infection.

Fig. 7. Endoscopic view of a gastrogastric fistula (the dashed line encircles the fistula).

Gastrogastric fistula

A gastrogastric fistula (GGF) is an abnormal communication between the gastric pouch and the excluded stomach (Fig. 7). It is an uncommon but potentially important complication after divided LRYGB, with an incidence ranging between 1.5% and 6.0%.[38,39] The most common symptom of GGF is inadequate weight loss or weight gain.[40] However, intractable marginal ulceration, recurrent UGI hemorrhage, pain and stricture formation can all herald the presence of a GGF.[39] The causes of GGF are varied, with iatrogenic, incomplete gastric transection likely to be the most common cause.[41] In addition, subclinical ASL from the gastrojejunal anastomosis or perforation of a marginal ulceration could possibly result in the formation of a GGF.[39]

Given the relative rarity of this complication and the myriad of possible presenting symptoms, any patients with persistent nausea, vomiting, insufficient weight loss, weight gain, intractable marginal ulceration, persistent epigastric pain, recurrent UGI hemorrhage and gastrojejunostomy anastomotic stricture should undergo UGI endoscopy and contrast UGI series to elucidate the problem. If the investigations reveal a GGF, these patients should be treated with proton pump inhibitors and sucralfate. This course of medical management has been shown to result in symptom resolution in 37% of patients who experience this complication.[39]

Symptomatic GGF will require surgical management using either a laparoscopic or open approach. Most experienced laparoscopic surgeons would opt for the minimally invasive approach, combining laparoscopy with intraoperative endoscopy to identify, isolate and transect the fistulous tract with an Endo GIA stapler.[42,43] However, recent reports

Table 1. Summary of recommendations

Postoperative period	Signs/symptoms	Differentials	Investigations/actions
Early	Sustained tachycardia (> 120 beats/min)	Anastomotic or staple line leak Substantial postoperative hemorrhage	Return to OR for diagnostic laparoscopy/laparotomy
	Bilious vomiting	R/O Roux-en-O configuration	HIDA scan with possible return to OR
	Abdominal pain and vomiting	R/O internal hernia	UGI series with possible return to OR
Late	Colicky abdominal pain after meals Excessive weight loss	R/O internal hernia	CT scan with possible return to OR for diagnostic laparoscopy
	Profound weight loss and vomiting	R/O anastomotic stricture	UGI series UGI endoscopy Nutritional testing Interventions based on results
	Weight gain	R/O gastrogastric fistula Noncompliance	UGI series UGI endoscopy Consider referral to specialized multidisciplinary bariatric team

CT = computed tomography; HIDA = hepatobiliary iminodiacetic acid; OR = operating room; R/O = reoperation; UGI = upper gastrointestinal.

of transgastric[44] and endoscopic[45,46] approaches using a through-the-scope endoclip repair have attracted some interest. However, there are limited data on the long-term durability or overall efficacy of these repairs.

Weight gain

Weight gain after bariatric surgery occurs in about 10% of patients after 5 years and in about 20% of patients after 10 years.[47] The cause of weight gain is likely to be multifactorial, but there may be some contribution from pouch dilatation or the presence of a GGF.[40,48] It has been demonstrated that lack of control over food urges, addictive behaviours, decreased overall postoperative well-being, lack of self-monitoring and fewer postoperative follow-up visits are associated with weight gain.[49] Ultimately, these patients will require a thorough evaluation in a bariatric multidisciplinary setting before any consideration of surgical reintervention to address the weight gain.

Nutritional deficiencies

Nutritional problems after LRYGB are features of the surgical model itself. The same changes of GI anatomy and physiology that reverse obesity can elicit imbalances owing to reduced oral intake or excessive losses secondary to reconfiguration of GI motility, pH and enzymatic profile.[50] Anemia is the most common complication and is estimated to occur in 20%–49% of patients after antiobesity operations.[51] In patients who undergo gastric bypass this is due to iron, folate and vitamin B12 deficiencies.[48] Major deficits were also noted in magnesium, calcium, zinc, 25-hydroxyvitamin D, thiamine and β-carotene.[48,50] Blood work is recommended to detect and monitor vitamin and mineral deficiencies. These patients require a referral to a registered dietitian for nutrition counselling, and lifelong vitamin and mineral supplementation is recommended.[52]

Conclusion

Laparoscopic Roux-en-Y gastric bypass is currently the gold-standard bariatric surgical procedure. Whereas it offers excellent long-term results, it is associated with clinically important early and late complications. As the volume of inpatient bariatric procedures increases, it is inevitable that patients experiencing these complications will present to nonbariatric general surgeons. This review offers a comprehensive evidence-based guide to the care of patients experiencing complications after LRYGB. A summary of recommendations is provided in Table 1. It is hoped that this will allow us to offer the best possible outcomes to these challenging patients.

Competing interests: None declared for P.S. Griffith, A.M. Sharma and S. Karmali. D.W. Birch declares having received consulting fees from Johnson & Johnson, Ethicon Endo-Surgery, Covidien and Baxter, as well as speaker fees from Covidien and Baxter.

Contributors: All authors designed the review, reviewed the article and approved its publication. P.S. Griffith acquired the data. P.S. Griffith and S. Karmali analyzed the data and wrote the article.

References

1. Canadian Health Measures Survey 2010. In: *Statistics Canada* [website of Statistics Canada]. Available: www.statcan.gc.ca/daily-quotidien/100113/dq100113a-eng.htm (accessed 2010 Nov. 30).
2. Katzmarzyk PT, Mason C. Prevalence of class I, II and III obesity in Canada. *CMAJ* 2006;174:156-7.
3. Arkinson J, Ji H, Fallah S, et al. Bariatric surgery in canada: a focus on day surgery procedures. *Healthc Q* 2010;13:15-8.
4. Flum DR, Dellinger EP. Impact of gastric bypass operation on survival: a population-based analysis. *J Am Coll Surg* 2004;199:543-51.
5. Pratt GM, Learn CA, Hughes GD, et al. Demographics and outcomes at American Society for Metabolic and Bariatric Surgery Centers of Excellence. *Surg Endosc* 2009;23:795-9.
6. Nguyen NT, DeMaria E, Ikramuddin S, et al., editors. *The SAGES Manual: A Practical Guide to Bariatric Surgery.* New York: Springer; 2008.
7. Rosenthal RJ, Szomstein S, Kennedy CI, et al. Laparoscopic surgery for morbid obesity: 1,001 consecutive bariatric operations performed at the Bariatric Institute, Cleveland Clinic Florida. *Obes Surg* 2006;16:119-24.
8. Mason EE, Ito C. Gastric bypass in obesity. *Surg Clin North Am* 1967;47:1345-51.
9. Ballesta C, Berindoague R, Cabrera M, et al. Management of anastomotic leaks after laparoscopic Roux-en-Y gastric bypass. *Obes Surg* 2008;18:623-30.
10. Papasavas PK, Caushaj PF, McCormick JT, et al. Laparoscopic management of complications following laparoscopic Roux-en-Y gastric bypass for morbid obesity. *Surg Endosc* 2003;17:610-4.
11. Fernandez AZ, DeMaria EJ, Tichansky DS, et al. Experience with over 3,000 open and laparoscopic bariatric procedures: multivariate analysis of factors related to leak and resultant mortality. *Surg Endosc* 2004;18:193-7.
12. Marshall JS, Srivastava A, Gupta SK, et al. Roux-en-Y gastric bypass leak complications. *Arch Surg* 2003;138:520-3.
13. Bellorin O, Abdemur A, Sucandy I, et al. Understanding the significance, reasons and patterns of abnormal vital signs after gastric bypass for morbid obesity. *Obes Surg* 2011;21:707-13.
14. Fullum TM, Aluka KJ, Turner PL. Decreasing anastomotic and staple line leaks after laparoscopic Roux-en-Y gastric bypass. *Surg Endosc* 2009;23:1403-8.
15. Madan AK, Martinez JM, Menzo EL, et al. Omental reinforcement for intraoperative leak repairs during laparoscopic Roux-en-Y gastric bypass. *Am Surg* 2009;75:839-42.
16. Gonzalez R, Sarr MG, Smith CD, et al. Diagnosis and contemporary management of anastomotic leaks after gastric bypass for obesity. *J Am Coll Surg* 2007;204:47-55.
17. DeMaria EJ, Sugerman HJ, Kellum JM, et al. Results of 281 consecutive total laparoscopic Roux-en-Y gastric bypasses to treat morbid obesity. *Ann Surg* 2002;235:640-5.

18. Kolakowski S, Kirkland ML, Schuricht AL. Routine postoperative upper gastrointestinal series after Roux-en-Y gastric bypass: determination of whether it is necessary. *Arch Surg* 2007;142:930-4.

19. Carter JT, Tafreshian S, Campos GM, et al. Routine upper GI series after gastric bypass does not reliably identify anastomotic leaks or predict stricture formation. *Surg Endosc* 2007;21:2172-7.

20. Sims TL, Mullican MA, Hamilton EC, et al. Routine upper gastrointestinal Gastrografin® swallow after laparoscopic Roux-en-Y gastric bypass. *Obes Surg* 2003;13:66-72.

21. Podnos YD, Jimenez JC, Wilson SE, et al. Complications after laparoscopic gastric bypass: a review of 3464 cases. *Arch Surg* 2003; 138:957-61.

22. Mehran A, Szomstein S, Zundel N, et al. Management of acute bleeding after laparoscopic Roux-en-Y gastric bypass. *Obes Surg* 2003; 13:842-7.

23. Nguyen NT, Rivers R, Wolfe BM. Early gastrointestinal hemorrhage after laparoscopic gastric bypass. *Obes Surg* 2003;13:62-5.

24. Higa KD, Ho T, Boone KB. Internal hernias after laparoscopic Roux-en-Y gastric bypass: incidence, treatment and prevention. *Obes Surg* 2003;13:350-4.

25. Schnieder C, Cobb W, Scott J, et al. Rapid excess weight loss following laparoscopic gastric bypass leads to increased risk of internal hernia. *Surg Endosc* 2011;25:1594-8.

26. Carmody B, DeMaria EJ, Jamal M, et al. Internal hernia after laparoscopic Roux-en-Y gastric bypass. *Surg Obes Relat Dis* 2005;1:543-8.

27. Steele KE, Prokopowicz GP, Magnuson T, et al. Laparoscopic antecolic Roux-en-Y gastric bypass with closure of internal defects leads to fewer internal hernias than the retrocolic approach. *Surg Endosc* 2008;22:2056-61.

28. Paroz A, Calmes JM, Giusti V, et al. Internal hernia after laparoscopic Roux-en-Y gastric bypass for morbid obesity: a continuous challenge in bariatric surgery. *Obes Surg* 2006;16:1482-7.

29. Sherman V, Dan AG, Lord JM, et al. Complications of gastric bypass: avoiding the Roux-en-O configuration. *Obes Surg* 2009;19:1190-4.

30. Goitein D, Papasavas PK, Gagne D, et al. Gastrojejunal strictures following laparoscopic Roux-en-Y gastric bypass for morbid obesity. *Surg Endosc* 2005;19:628-32.

31. Alasfar F, Sabnis AA, Liu RC, et al. Stricture rate after laparoscopic Roux-en-Y gastric bypass with a 21-mm circular Stapler: The Cleveland Clinic Experience. *Med Princ Pract* 2009;18:364-7.

32. Mathew A, Veliuona MA, DePalma FJ, et al. Gastrojejunal stricture after gastric bypass and efficacy of endoscopic intervention. *Dig Dis Sci* 2009;54:1971-8.

33. Nguyen NT, Stevens CM, Wolfe BM. Incidence and outcome of anastomotic stricture after laparoscopic gastric bypass. *J Gastrointest Surg* 2003;7:997-1003.

34. Kravetz AJ, Reddy S, Murtaza G, et al. A comparative study of hand-sewn versus stapled gastrojejunal anastomosis in laparoscopic Roux-en-Y gastric bypass. *Surg Endosc* 2011;25:1287-92.

35. Sapala JA, Wood MH, Sapala MA, et al. Marginal ulcer after gastric bypass: a prospective 3-year study of 173 patients. *Obes Surg* 1998;8: 505-16.

36. Csendes A, Burgos AM, Altuve J, et al. Incidence of marginal ulcer 1 month and 1 to 2 years after gastric bypass: a prospective consecutive endoscopic evaluation of 442 patients with morbid obesity. *Obes Surg* 2009;19:135-8.

37. Rasmussen JJ, Fuller W, Ali MR. Marginal ulceration after laparoscopic gastric bypass: an analysis of predisposing factors in 260 patients. *Surg Endosc* 2007;21:1090-4.

38. Cucchi SG, Pories WJ, MacDonald KG, et al. Gastrogastric fistulas. A complication of divided gastric bypass surgery. *Ann Surg* 1995;221: 387-91.

39. Tucker ON, Szomstein S, Rosenthal RJ. Surgical management of gastro–gastric fistula after divided laparoscopic Roux-en-Y gastric bypass for morbid obesity. *J Gastrointest Surg* 2007;11:1673-9.

40. Yao DC, Stellato TA, Schuster MM, et al. Gastrogastric fistula following Roux-en-Y bypass is attributed to both surgical technique and experience. *Am J Surg* 2010;199:382-5.

41. Gould JC, Garren MJ, Starling JR. Lessons learned from the first 100 cases in a new minimally invasive bariatric surgery program. *Obes Surg* 2004;14:618-25.

42. Júnior WS, Pitanga CK, Borges CN, et al. Treatment of gastrogastric fistula after Roux-en-Y gastric bypass: surgery combined with gastroscopy. *Obes Surg* 2007;17:836-8.

43. Filho AJ, Kondo W, Nassif LS, et al. Gastrogastric fistula: a possible complication of Roux-en-Y gastric bypass. *JSLS* 2006;10:326-31.

44. Torres-Villalobos G, Leslie DB, Hunter D, et al. Preliminary report: search for a transgastric approach for managing gastrogastric fistulas. *World J Surg* 2011;35:372-6.

45. Bhardwaj A, Cooney RN, Wehrman A, et al. Endoscopic repair of small symptomatic gastrogastric fistulas after gastric bypass surgery: a single center experience. *Obes Surg* 2010;20:1090-5.

46. Fernandez-Esparrach G, Lautz DB, Thompson CC. Endoscopic repair of gastrogastric fistula after Roux-en-Y gastric bypass: a less-invasive approach. *Surg Obes Relat Dis* 2010;6:282-8.

47. Christou NV, Look D, Maclean LD. Weight gain after short and long limb gastric bypass in patients followed for longer than 10 years. *Ann Surg* 2006;244:734-40.

48. Lopez PP, Patel NA, Koche LS. Outpatient complications encountered following Roux-en-Y gastric bypass. *Med Clin North Am* 2007;91:471-83.

49. Odom J, Zalesin KC, Washington TL, et al. Behavioral predictors of weight regain after bariatric surgery. *Obes Surg* 2010;20:349-56.

50. Dalcanale L, Oliveira CP, Faintuch J, et al. Long-term nutritional outcome after gastric Bypass. *Obes Surg* 2010;20:181-7.

51. Aills L, Blankenship J, Buffington C, et al.; Allied Health Sciences Section Ad Hoc Nutrition Committee. ASMBS Allied Health Nutritional Guidelines for the surgical weight loss patient. *Surg Obes Relat Dis* 2008;4(Suppl):S73-108.

52. Karmali S, Johnson Stoklossa C, Sharma A, et al. Bariatric surgery: a primer. *Can Fam Physician* 2010;56:873-9.