

# Phyllodes tumour of the breast and margins: How much is enough?

Samuel Ogunbiyi, MBBS, MD  
Andrew Perry, MD  
Kiran Jakate, MD  
Jory Simpson, MD, MEd  
Ralph George, MD

Accepted July 27, 2018

## Correspondence to:

S. Ogunbiyi  
Department of General Surgery  
St. Michael's Hospital  
30 Bond St.  
Toronto ON M5B 1W8  
samuelogunbiyi@gmail.com

DOI: 10.1503/cjs.005718

## SUMMARY

Phyllodes breast tumours are fairly uncommon, and they can be benign, borderline or malignant. General surgeons usually encounter them following the surgical excision of a breast lump that had the appearance of a fibroepithelial lesion. The surgeon is then faced with the question of what to do to establish an acceptable treatment margin. In this discussion, we recommend a plan for the management of Phyllodes tumours based on a review of the recent literature, confirmed by a retrospective review of the results from our centre. A negative margin is acceptable treatment following a lumpectomy for Phyllodes tumours. Only patients with a positive margin should undergo a revision.

**P**hyllodes tumours are an uncommon type of fibroepithelial neoplasm of the breast, with a reported incidence of less than 1%.<sup>1,2</sup> Because this type of tumour is uncommon, most clinicians have relied on data from small, retrospective studies to guide management decisions.

Traditionally, the National Comprehensive Cancer Network (NCCN) guidelines have advocated a wide local excision with margins of 1 cm or more, without axillary staging to treat Phyllodes tumours of the breast.<sup>3</sup> This is in sharp contrast to the NCCN guidelines adopted in 2014 for invasive cancer, accepting no tumour on ink as sufficient margins.<sup>3</sup> For invasive cancer, studies have shown a clear link between positive margins and local recurrence.<sup>4</sup> In a multicentre study, Co and colleagues<sup>5</sup> showed a similar link between positive margins and local recurrence for Phyllodes tumours. In the clinical setting, most surgeons encounter Phyllodes tumours in the context of the management of fibroepithelial tumours of the breast.

So, what does the general surgeon do for the patient with a pathological diagnosis of Phyllodes tumour of the breast? How much of a margin of normal tissue is considered to be enough?

## WHAT DOES THE LITERATURE TELL US?

The data available in literature on Phyllodes tumours include retrospective reviews and large, single-centre studies.<sup>5-9</sup> The following points summarize what these studies tell us about the management of Phyllodes tumours:

- Prognosis is excellent for Phyllodes tumours following surgical excision, with no requirement for adjuvant therapy.<sup>5,6</sup>
- As long as the microscopic surgical margins are free of disease, the extent of surgery does not correlate with disease-free survival or local recurrence.<sup>7,8</sup>
- Distant recurrences are more frequent in patients with malignant tumours.<sup>5</sup>
- The upgrade rate of fibroepithelial lesions to Phyllodes tumours following a period of observation is low.<sup>9</sup>

We performed a retrospective review at our single tertiary referral centre of all patients who had undergone surgical therapy for Phyllodes

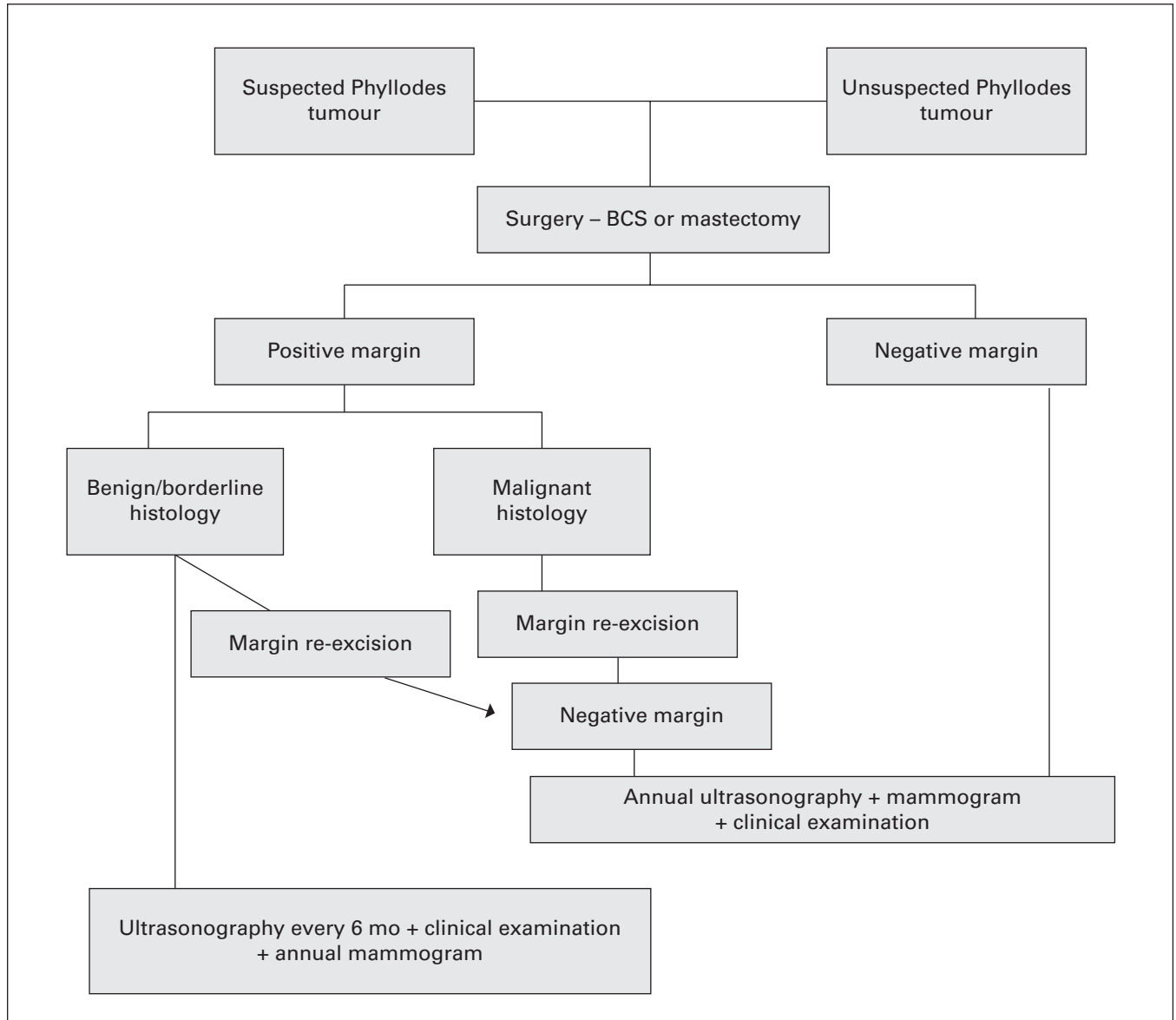


Fig. 1. Phyllodes tumour of the breast: management and decision-making algorithm. BCS = breast-conserving surgery.

tumours between May 2009 and June 2015 (Appendix 1, available at [canjsurg.ca/005718-a1](http://canjsurg.ca/005718-a1)). The largest subgroup of patients available for analysis was the group with benign Phyllodes tumours ( $n = 52$ ; Appendix 1). In this group, 21 (40%) patients had close, negative margins, and 20 (38%) had positive margins on the initial surgical excision. One-third of the patients with positive margins ( $n = 7$ ) underwent a margin re-excision and the rest ( $n = 13$ ) opted to undergo a wait and watch policy with close observation. All patients with malignant Phyllodes tumours ( $n = 4$ ) and a positive margin ( $n = 1$ ) were offered further surgery to clear the margin.

The local recurrence rate for the whole cohort of patients was 1.9% ( $n = 1$ ); this patient had a benign Phyllodes tumour with a positive margin and opted for a wait and watch policy with close surveillance.

### WHAT SHOULD SURGEONS DO FOR NOW?

The setting in which most general surgeons encounter Phyllodes tumours of the breast is in the context of a core biopsy from a breast lump or a fibroepithelial lesion that is surgically excised. Based on the data available in literature, as well as the findings from our investigation, we propose an algorithm for the management of suspected and unsuspected Phyllodes tumours of the breast (Fig. 1) and suggest the following:

- The NCCN guidelines advocating a 1 cm margin for surgical therapy for Phyllodes tumours is over-treatment.
- Surgeons should request that pathologists classify the Phyllodes tumours as benign, borderline or malignant breast tumours in their reports.

- Patients with a microscopically negative margin following a lumpectomy for Phyllodes tumours require no adjuvant therapy and can be followed up with annual surveillance.
- Patients with a positive margin can be treated with margin re-excision or close surveillance if they have benign or borderline histology.
- Patients with a positive margin and malignant histology should undergo further surgery to obtain clear margins.

**Acknowledgements:** The authors thank Dr. Jesse McLean, research manager at the Royal Victoria regional hospital, for his help with the data presentation and manuscript preparation. They also thank Miss Emma Hawkes for her help with collecting and charting the data used for the study.

**Affiliations:** From the Department of General Surgery, University of Toronto, Toronto, Ont.

**Competing interests:** None declared.

**Contributors:** All authors contributed substantially to the conception, writing and revision of this article and approved the final version for publication.

## References

1. Kario K, Maeda S, Mizuno Y, et al. Phyllodes tumour of the breast: a clinicopathological study of 34 cases. *J Surg Oncol* 1990;45:46-51.
2. Rowell MD, Perry RR, Hsiu JG, et al. Phyllodes tumours. *Am J Surg* 1993;165:376-9.
3. National Comprehensive Cancer Network. Phyllodes tumor, version 1.2018. Plymouth Meeting (PA): NCCN; 2018.
4. Singletary SE. Surgical margins in patients with early stage breast cancer treated with breast conservation therapy. *Am J Surg* 2002;184:383-93.
5. Co M, Chen C, Tsang JY, et al. Phyllodes tumour: a 15 year multi-center clinical review. *J Clin Pathol* 2018;71:493-7.
6. Spitaleri G, Toesca A, Botteri E, et al. Breast phyllodes tumor: a review of literature and a single center retrospective series analysis. *Crit Rev Oncol Hematol* 2013;88:427-36.
7. Mitus J, Reinfuss M, Mitus JW, et al. Malignant phyllodes tumor of the breast: treatment and prognosis. *Breast J* 2014;20:639-44.
8. Shaaban M, Barthelmes L. Benign phyllodes tumors of the breast: (over) treatment of margins — a literature review. *Eur J Surg Oncol* 2017;43:1186-90.
9. Van Osdol AD, Landercasper J, Andersen JJ, et al. Determining whether excision of all fibroepithelial lesions of the breast is needed to exclude phyllodes tumor: upgrade rate of fibroepithelial lesions of the breast to phyllodes tumor. *JAMA Surg* 2014;149:1081-5.