

# Intermittent use of resuscitative endovascular balloon occlusion of the aorta in penetrating gunshot wound of the lower extremity

Omar Bekdache, MD  
Tiffany Paradis, BSc  
David Bracco, MD  
Aly Elbahrawy, MD  
Kosar Khwaja, MD  
Dan L. Deckelbaum, MD  
Paola Fata, MD  
Andrew Beckett, MD, MSc  
Tarek Razek, MD  
Jeremy Grushka, MD, MSc

Accepted March 5, 2019

## Correspondence to:

T. Paradis  
Montreal General Hospital  
1650 Cedar Ave  
Montreal QC H3G 1A4  
tiffany.paradis@mail.mcgill.ca

DOI: 10.1503/cjs.017018

## SUMMARY

The use of resuscitative endovascular balloon occlusion of the aorta (REBOA) in penetrating injuries is an emerging adjunct in the civilian trauma surgeon's toolbox for the management of traumatic hemorrhagic shock. Furthermore, within the Canadian civilian context, little has been reported with regard to its use as an assisted damage-control measure in vascular reconstruction of the lower extremity. We report a case of penetrating gunshot injury of the lower extremity where the preoperative deployment of REBOA had a remarkable positive impact in the resuscitation phase and the intraoperative control of blood loss. A description of the procedure and the advantage gained from REBOA are discussed.

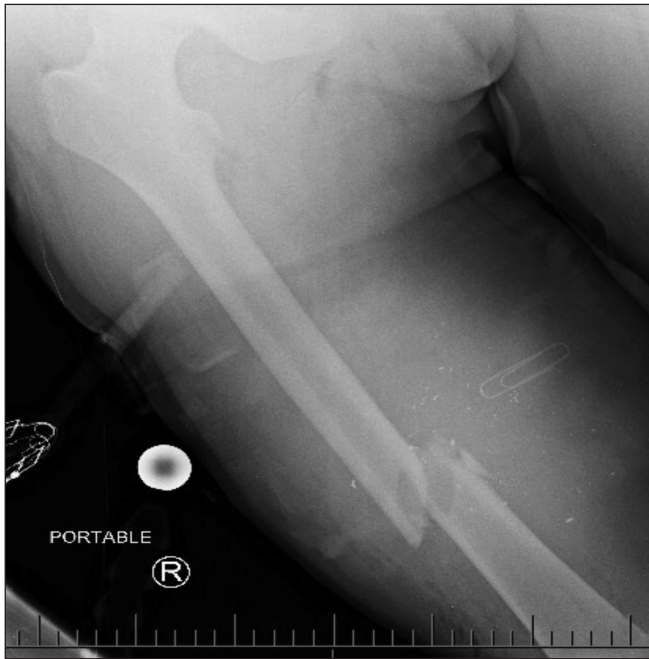**H**emorrhage is the leading cause of preventable death in trauma casualties. Early control of hemorrhage in traumatic injuries is paramount to improving the likelihood of survival.<sup>1</sup> Initially, this can be achieved with direct pressure or a tourniquet in compressible injuries; in contrast, non-compressible or difficult-to-access areas can be challenging. The use of resuscitative endovascular balloon occlusion of the aorta (REBOA) in severely injured, bleeding trauma patients is an exciting adjunct for hemorrhage control. This technique constitutes a helpful damage-control measure that allows for temporary control of blood flow to specific areas of the body to gain time for more definitive management. While its role is being more defined in blunt trauma to the torso, use of REBOA in penetrating trauma, especially to the lower extremity, is not well established.

## CASE REPORT

A 27-year-old man sustained an isolated gunshot wound to the right thigh. He was found in profound hemorrhagic shock by first responders. Compressive tourniquet application was difficult owing to the natural girth of the patient's leg and the development of a hematoma at the site of injury. The soft tissue damage and girth of the right thigh prevented proper hemorrhage control via tourniquet. The patient underwent hemostatic resuscitation in accordance with our institutional massive transfusion protocol. A single through-and-through gunshot wound to the right mid-thigh was noted on secondary survey.

After rapid imaging of the chest and right thigh, a decision was made to take the patient immediately to the operating room (Fig. 1). To gain proximal control of the bleeding vessel, REBOA was deployed in aortic infrarenal zone III. Ultrasound-guided access to the left common femoral artery was obtained, and a REBOA catheter was advanced to 31 cm. The balloon was inflated using 6 mm of saline. Time from skin puncture to REBOA inflation was 37 seconds. There was a simultaneous improvement of the patient's hemodynamics. Balloon position was confirmed to zone III using intraoperative fluoroscopy. A

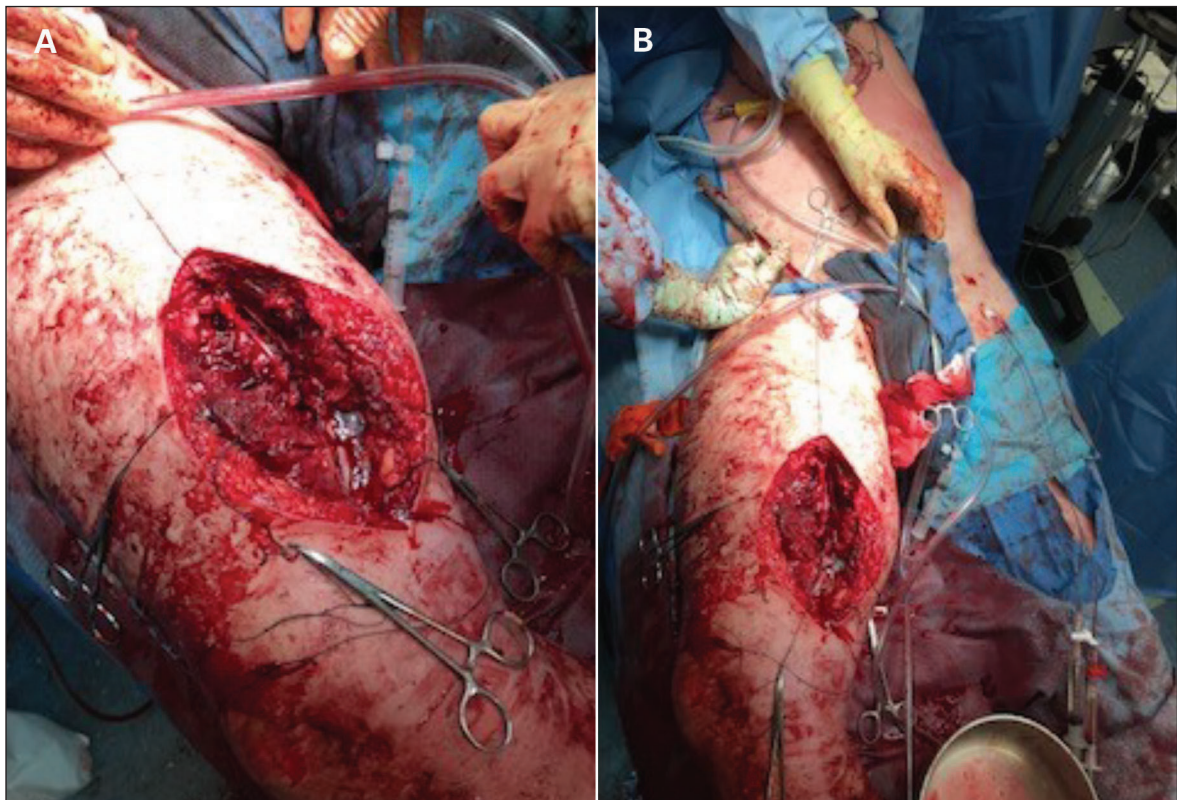
medial longitudinal approach was used, centred by the medial aperture wound and a very large hematoma was discovered and evacuated. Soft tissue injury of the underlying



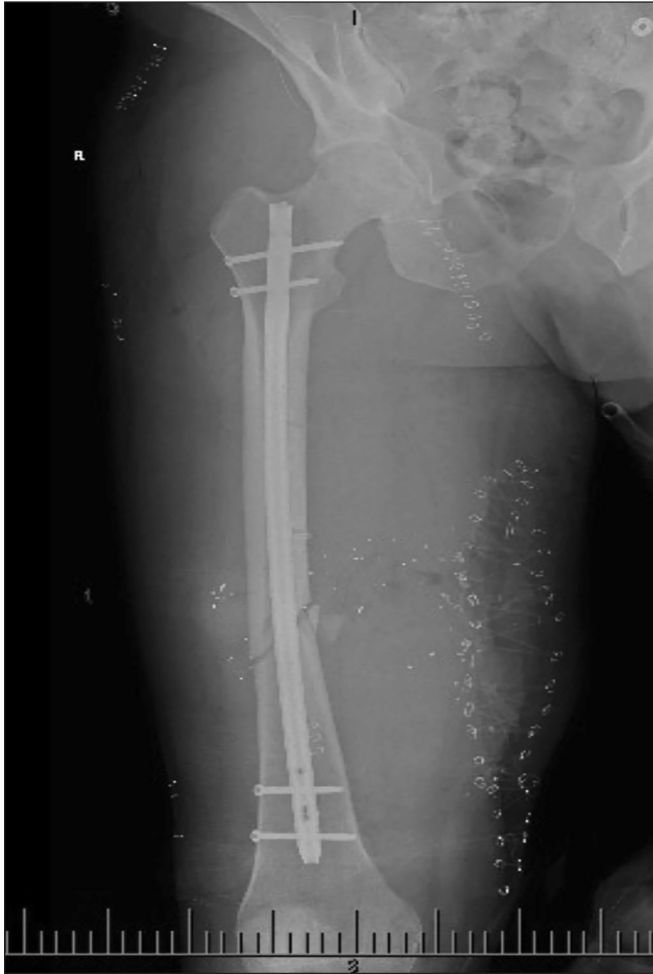**Fig. 1.** Preoperative radiograph showing a comminuted fracture of the right femur and shrapnel from the ballistic injury. The medial aperture is marked with a metallic paper clip.

muscle and a comminuted fracture of the right femur were observed. There was a complete transection of the superficial femoral artery and the femoral vein adjacent to the fracture site. A gap of 5 cm between proximal and distal vascular ends was observed in both transected vessels. The identification of the proximal arterial and venous vessel stumps was markedly aided by intermittent deflation and inflation of the REBOA balloon. A decision was made to temporarily shunt the artery to assure the continuity of vascular supply to the lower extremity. This was achieved using a 12 cm 10-French Argyle catheter (Fig. 2). The transected femoral vein was ligated. After securing the shunt and deflating the balloon, the orthopedic surgery team placed an external fixator to realign the shattered femur. At this point, the patient's clinical status was re-evaluated, and no further blood transfusions were required following REBOA deployment. Moreover, all vasopressors had been discontinued, and there was complete normalization of both the patient's hemodynamics (blood pressure 125/83 mm Hg and heart rate 87 beats/min) and lactate (1.5 mmol/L).

Given these findings, the decision was made to perform a definitive vascular repair. A 7 cm section of saphenous vein was harvested from the contralateral left thigh and was grafted in a reversed fashion to the proximal and distal arterial stumps using standard vascular techniques. A 4-compartment fasciotomy of the right lower extremity



**Fig. 2.** A) Intraoperative picture of the shunted superficial femoral artery. B) Resuscitative endovascular balloon occlusion of the aorta catheter shown accessing the left groin. Note the shunted vessel and the deformed, swollen thigh.

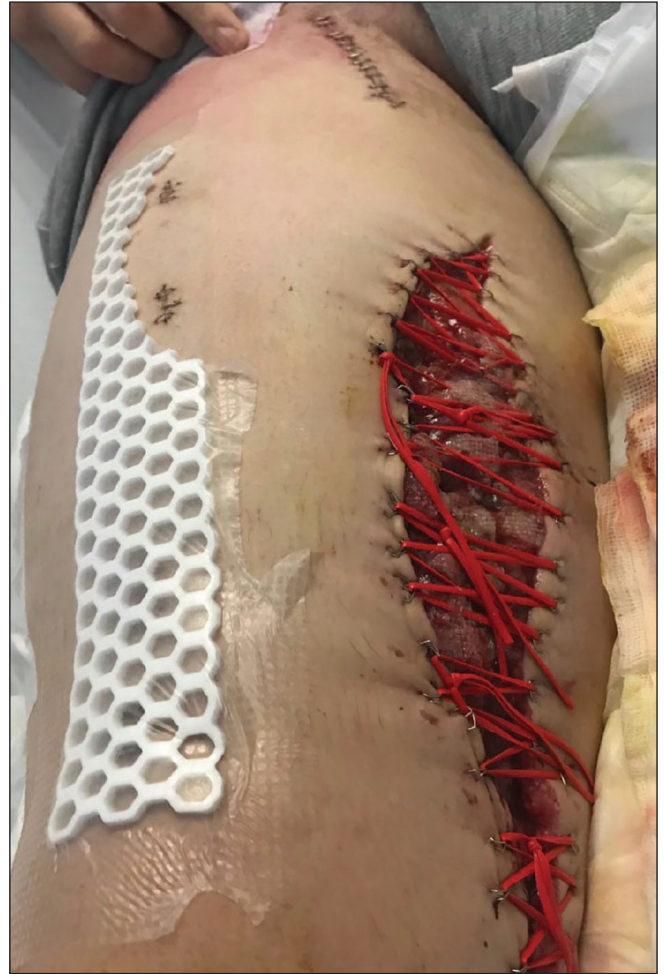

**Fig. 3.** Definitive interval orthopedic fixation with intramedullary interlocking nail. Note the metallic clips marking the medial initial approach.

was performed to prevent compartment syndrome. Total inflation time was 19 minutes, with an initial inflation of 17 minutes followed by temporary deflation and an additional re-inflation for 2 minutes. The REBOA catheter was removed at the conclusion of the procedure, leaving the introducer sheath inside the common femoral artery for 12 hours following the procedure. The patient received 14 units of packed red blood cells, 10 units of fresh frozen plasma and 10 units of platelets before REBOA deployment, and no transfusion products after REBOA. The patient returned to the operating room for open reduction and internal fixation of his fractured right femur on postoperative day 5 (Fig. 3). He was followed on the ward for further wound care (Fig. 4). No complications were attributed to the REBOA catheter placement.

## DISCUSSION

The principle of REBOA as a method of hemorrhage control was first described by Dr. Carl Hughes during the Korean war.<sup>2</sup> Although the first patients succumbed to their



**Fig. 4.** Postoperative wound left open for gradual bedside tightening.

wounds, the potential for its use as a resuscitative method was demonstrated. The use of REBOA is not as well described in penetrating trauma as in blunt trauma. An early case series by Gupta and colleagues reporting on the use of an intraaortic balloon occlusion in penetrating trauma demonstrated that 7 of 21 consecutive patients with missile injuries survived the procedure.<sup>3</sup> A meta-analysis by Manzano and colleagues examined 1276 cases of penetrating injuries in which the use of REBOA was reported in only 56 patients.<sup>4</sup> Branco and colleagues showed that REBOA is a safe and effective alternative to open thoracotomy in critically ill trauma patients with penetrating abdominal trauma.<sup>5</sup> Partial and intermittent REBOA has been described in the literature. The balloon was either partially or completely deflated at regular intervals to momentarily restore distal blood flow in an attempt to reduce the incidence of ischemic and reperfusion events.<sup>6,7</sup> We describe the first use of REBOA as an adjunct to hemorrhage control for penetrating trauma in Canada. Our report highlights the advantage of using REBOA in penetrating lower extremity trauma for severely injured patients

in extremis. The use of REBOA allowed for hemorrhagic arrest, accelerated hemostatic resuscitation and facilitated the identification of injured vessels in a hostile surgical field

### CONCLUSION

REBOA constitutes an additional measure available to emergency department physicians and trauma surgeons. Selective use of REBOA as a damage-control tool should be tailored to the patients' physiology. The possible advantage in controlling hemorrhage from lower extremity injuries in patients in profound hemorrhagic shock, as illustrated in this case, is worth consideration.

**Acknowledgements:** The authors acknowledge the support of the Montreal General Hospital Foundation, the McGill University Health Centre Emergency Medicine and Adult Trauma Programs.

**Affiliations:** From the Trauma Program, McGill University Health Centre, Montreal, Que. (Beckett, Bekdache, Bracco, Elbahrawy, Khwaja, Deckelbaum, Fata, Razek, Grushka); the Faculty of Medicine, McGill University, Montreal, Que. (Paradis); the Medical Research Institute, Alexandria University, Alexandria, Egypt (Elbahrawy); and the Royal Canadian Medical Services, Montreal, Que. (Beckett).

**Competing interests:** D. Deckelbaum and A. Beckett are *C7S* associate editors. They were not involved in the review of this manuscript or in the decision to accept it for publication. No other competing interests declared.

**Contributors:** All authors contributed substantially to the conception, writing and revision of this article and approved the final version for publication.

### References

1. Meizoso JP, Ray JJ, Karcutskie CA 4th, et al. Effect of time to operation on mortality for hypotensive patients with gunshot wounds to the torso: The golden 10 minutes. *J Trauma Acute Care Surg* 2016;81:685-91.
2. Hughes CW. Use of an intra-aortic balloon catheter tamponade for controlling intra-abdominal hemorrhage in man. *Surgery* 1954; 36:65-8.
3. Gupta BK, Khaneja SC, Flores L, et al. The role of intra-aortic balloon occlusion in penetrating abdominal trauma. *J Trauma* 1989;29:861-5.
4. Manzano NR, Naranjo MP, Foianini E, et al. A meta-analysis of resuscitative endovascular balloon occlusion of the aorta (REBOA) or open aortic cross-clamping by resuscitative thoracotomy in non-compressible torso hemorrhage patients. *World J Emerg Surg* 2017; 12:30.
5. Branco BC, DuBose JJ. Endovascular solutions for the management of penetrating trauma: an update on REBOA and axillo-subclavian injuries. *Eur J Trauma Emerg Surg* 2016;42:687-69.
6. Morrison JJ, Ross JD, Houston RT, et al. Use of resuscitative endovascular balloon occlusion of the aorta in a highly lethal model of noncompressible torso hemorrhage. *Shock* 2014;41:130-7.
7. Hörer TM, Cajander P, Jans A, et al. A case of partial aortic balloon occlusion in an unstable multi-trauma patient. *Trauma* 2016; 18:150-4.